

**ROUND TABLE**

**96<sup>TH</sup> NATIONAL CONGRESS**

**ITALIAN SOCIETY OF OTORHINOLARYNGOLOGY AND CERVICO-FACIAL SURGERY (S.I.O. E CH.C.F.)**

**RIMINI, MAY 13-16, 2009**

# **Deglutition and phonatory function recovery following partial laryngeal surgery: speech therapy methods and surgical techniques**

*Il recupero della funzione deglutitoria e fonatoria dopo chirurgia parziale della laringe: metodiche logopediche e tecniche chirurgiche*

MODERATOR: L. PRESUTTI (MODENA)

PROCEEDINGS EDITED BY: L. PRESUTTI, G. BERGAMINI

ENT Department, University Hospital of Modena, Italy

## **SUMMARY**

Since the introduction of laryngeal surgery, practitioners have recognised the need for the rehabilitation of the two essential functions of the laryngeal system: swallowing and speech. In the early 1950s and then in 1970, European including Italian Authors established further milestones in conservative laryngeal surgery.

*Physiological anatomy of the operated larynx:* A correct knowledge of the anatomy and physiology of the operated larynx is fundamental to the success of functional laryngeal cancer surgery. Herewith, an analysis is made of the anatomical and physiological foundation of the larynx in a multifactorial approach: the anatomical and physiological foundation of this kind of surgery is the cricoarytenoid unit (CAU). This structure has both a "classic" and an "updated" definition.

These notes illustrate how the functional outcome, following laryngeal cancer surgery, relies on respecting all the elements in that constellation of factors that permit minimal anatomic and functional dignity of the neolarynx.

*Speech therapy rehabilitation:* An analysis is made of the speech therapy rehabilitation programme; the purposes of re-education are: activation of the deglutition mechanisms, arytenoid mobilisation and activation of arytenoid mucosal vibration. We analyze the different steps of the rehabilitation programme that starts with diagnosis and continues during hospitalisation and after the patient's discharge.

*Surgical rehabilitation:* Another important chapter is the surgical rehabilitation. In fact, for many years, the alternative to functional procedures in which the glottic or supraglottic level are preserved (cordectomy of varying extents, supraglottic horizontal laryngectomy) was total laryngectomy, as replacement sphincteric function was not believed to be possible. In some cases, due to the persistence of swallowing difficulties, with progressive weight loss and the occurrence of repeated episodes of aspiration with bronchopneumonic complications, use of PEG can represent a provisional measure to allow an extension of the rehabilitation programme. If the functional situation does not improve sufficiently to allow adequate, risk-free eating, patients are often offered total laryngectomy. Since the late 1980s, some Authors have suggested surgical methods that aim to improve neoglottic competence and, consequently, the functions (swallowing and voice) related to the sphincteric ability of the larynx. This functional rehabilitation surgery is gradually being adopted, after the early experiences based exclusively on injective laryngoplasty techniques, in the light of more detailed evaluations of the various causes of deglutition failure. Moreover, only with injective methods is it possible to find solutions to minimal pre- and post-deglutition disorders. In parallel with the attempts to solve the problems of neoglottic insufficiency, a voice surgery technique has been developed with the aim of improving glottic competence following cordectomy to improve voice quality and eliminate the phonoasthenia that often represents the greatest handicap for these patients.

*Functional evaluation protocol and our caseload:* For all these reasons, it is very important to evaluate the impact that surgery can have in terms of dysphagia and, when possible, the need to quantify it, in relation also to the patient's quality of life. Correct deglutition, in fact, is the result of a precise coordination of the many structures present in the head and neck. Therefore, we analyse in detail the functional protocol, correlated with the data in our series, that is broken down into the analysis of the fundamental functions of the pharyngolaryngeal organ, i.e., an evaluation of swallowing, speech and respiratory functions, which together contribute to influencing the patient's quality of life.

**KEY WORDS:** Larynx • Partial laryngectomy • Swallowing • Phonation • Rehabilitation

## **RIASSUNTO**

*Alla base della chirurgia laringea vi è la necessità della riabilitazione di due delle funzioni fondamentali legate al viscere laringeo: la deglutizione e la fonazione. È a partire dagli anni '50 e successivamente negli anni '70 che si posero ulteriori capisaldi nella chirurgia conservativa laringea.*

*Anatomofisiologia della laringe operata: Alla base del successo della chirurgia oncologica funzionale della laringe vi è una corretta*

*conoscenza dell'anatomo-fisiologia della laringe operata. Nel lavoro che segue partiremo analizzando quelle che sono le basi anatomo-fisiologiche in maniera multifattoriale, ponendo attenzione al fondamento anatomo-fisiologico di tale chirurgia rappresentato dall'Unità Crico-Aritenoidea; di questa struttura si può fornire una definizione "classica" ed una definizione "attualizzata". Si evince come il favorevole esito funzionale dopo chirurgia funzionale oncologica della laringe derivi dal rispetto di tutti i fattori che consentono dignità anatomico funzionale ad un neo-laringe "a minima".*

*Riabilitazione logopedia: A seguire analizzeremo il percorso riabilitativo logopedico, i cui scopi sono l'attivazione del meccanismo deglutitorio, la mobilitazione aritenoidea e l'attivazione della vibrazione della mucosa aritenoidea. Analizzeremo quindi i vari steps dell'iter riabilitativo logopedico che inizia al momento della diagnosi, prosegue durante il ricovero e si protrae dopo la dimissione dal reparto ospedaliero.*

*Riabilitazione chirurgica: Altro capitolo fondamentale riguarda la riabilitazione chirurgica. Per molto tempo infatti l'alternativa agli interventi funzionali con conservazione del piano glottico o sopraglottico (cordectomia più o meno allargata, laringectomia orizzontale sopraglottica) è stata la laringectomia totale perché non si riteneva possibile una funzione sfinterica sostitutiva. In alcuni casi, per il protrarsi della difficoltà deglutitoria con calo ponderale progressivo e per il verificarsi di ripetuti episodi di aspirazione con complicanze broncopneumoniche, il ricorso alla PEG può costituire una misura provvisoria per consentire un prolungamento dell'iter riabilitativo; se la situazione funzionale non migliora consentendo una alimentazione adeguata e senza rischi la laringectomia totale è spesso la soluzione che viene prospettata al paziente. Alcuni Autori fin dalla fine degli anni '80 hanno proposto metodiche chirurgiche finalizzate a migliorare la competenza neoglottica e di conseguenza le funzioni (deglutizione e voce) correlate con la capacità sfinterica della laringe. Questa chirurgia di riabilitazione funzionale sta trovando una sistematizzazione dopo iniziali esperienze basate esclusivamente su tecniche di laringoplastica iniettiva alla luce di valutazioni più approfondite delle varie cause del fallimento deglutitorio. Parallelamente ai tentativi di soluzione delle insufficienze neoglottiche si è sviluppata una fonochirurgia finalizzata al miglioramento della competenza glottica dopo cordectomia per migliorare la qualità vocale ed eliminare la fonostenia che costituisce talvolta l'handicap maggiore per questi pazienti.*

*Protocollo di valutazione funzionale e casistica: Appare pertanto evidente la necessità di valutare l'impatto che la chirurgia comporta in termini di disfagia, e qualora sia possibile la necessità di quantificarla, anche in relazione alla qualità della vita del paziente. Una corretta deglutizione è infatti il risultato di una precisa coordinazione di molteplici strutture del distretto testa-collo. Pertanto analizzeremo in dettaglio, correlandolo ai dati della nostra casistica, il protocollo di valutazione funzionale che si articola nell'analisi delle funzioni fondamentali dell'organo faringo-laringeo, ossia la valutazione della funzionalità deglutitoria, fonatoria e respiratoria, che insieme concorreranno a influenzare la qualità della vita del paziente in esame.*

PAROLE CHIAVE: *Laringe • Laringectomia parziale • Deglutizione • Fonazione • Riabilitazione*

Acta Otorhinolaryngol Ital 2010;30:235-258

Received: July 20, 2010 - Accepted: August 20, 2010

## ROUND TABLE S.I.O. NATIONAL CONGRESS

# Introduction

## Introduzione

L. PRESUTTI, M. ALICANDRI-CIUFELLI

ENT Department, University Hospital of Modena, Italy

Since the advent of laryngeal surgery, practitioners have recognised the need for the rehabilitation of the two essential functions of the laryngeal system: swallowing, which for obvious reasons is necessary for survival; and speech, our main means of communication and, consequently, essential for interpersonal relationships. Although the first true laryngectomy, performed by Billroth, is conventionally thought to have been conducted in 1873<sup>1</sup> phonatory rehabilitation techniques were described for the first time in the early 1900s<sup>1</sup> and involved the use of aids such as the artificial larynx devised by Gussenbauer and Caselli<sup>1</sup> and those involving nasal or oral tubes (used by Gluck, Caselli and Tapia<sup>1</sup>): by suitably arranging the upper resonators and appropriately deviating the flow of exhaled air, patients

who had undergone total laryngectomy were able to produce an articulated, yet audible voice<sup>1</sup>. In the early decades of the 20<sup>th</sup> Century, in addition to rehabilitation techniques involving implanted aids, speech therapy rehabilitation techniques aimed at producing a belched voice were devised and later developed. The first attempts at combined surgical-implant rehabilitation were made by Delavan (in 1924)<sup>1</sup> and Briani (in 1952)<sup>1</sup>. Like their predecessors, these Authors used implants, this time integrating them with the patient's tissues in surgical procedures<sup>1</sup>.

At the same time, to overcome the significant functional consequences of laryngectomy, important progress was made in laryngeal surgery techniques by primarily European Authors starting in the 1950s, with the introduc-

tion of the vertical partial laryngectomy and supraglottic laryngectomy<sup>1-4</sup>. Whereas most modern laryngologists have abandoned the vertical technique on account of its high post-operative stenosis rates and subsequent frequent impossibility of decannulation, horizontal supraglottic laryngectomy, on the other hand, has become part of daily practice in the head and neck surgery field and as it spares the glottis, it poses far less important issues with regards to rehabilitation, the true focus of this Round Table.

In the early 1970s, Italian Authors, particularly Staffieri and Serafini, established further milestones in conservative laryngeal surgery<sup>1</sup>. The technique introduced by Staffieri involved the creation of a phonatory neoglottis during total laryngectomy procedures: this brought significant benefits for patients, making it possible to obtain a perfectly audible voice simply by closing the tracheostomy stoma during expiration to allow the air to vibrate the surgically-furnished valve between the trachea and the neo-hypopharynx. In 1970, Serafini<sup>1</sup>, on the other hand, presented the results of a laryngectomy with tracheohyoidopexy reconstruction: which, together with Mayer's experience (1959)<sup>2</sup>, was the first attempt at avoiding a permanent tracheostomy in subtotal laryngectomy subjects. Although Staffieri's laryngectomy technique frequently gave unsatisfactory results with belched voice production and Serafini's technique was characterised by a high post-operative pulmonary aspiration rate, these procedures, nevertheless, represented attempts that stimulated later surgeons to improve their methods and led us to the results we have today. Undoubtedly, Serafini can be credited with having believed in the potential of subtotal surgery, encouraging many laryngologists in Italy and worldwide to adopt the technique. A number of changes were later introduced to Serafini's original procedure: the tracheohyoidopexy technique thus evolved and, as experience developed, increasingly precise oncological indications were classified and, once the main aim of decannulation was achieved, increasingly safe and encouraging results were obtained in cancer patients. Indeed, in 1971, Alaimo, Labayle and Bismuth<sup>3</sup> published their reports on the cricohyoidopexy technique, and, in 1974, Piquet, Desaulty and Decroix published the results of their experience with a cricohyoidopexy procedure<sup>4</sup>. Despite involving the removal of most of the laryngeal structures, preserving just

the cricoid and at least one of the arytenoids, these procedures were a success from both an oncological and a functional standpoint. These Authors observed that the swallowing competence of the neoglottis was guaranteed even with just one arytenoid that by "bowing" towards the epiglottis or base of the tongue was able to adequately protect the respiratory tract. The same mobility of the residual arytenoid or arytenoids made it possible to obtain "compensation" voices perfectly adequate for normal interpersonal relationships, by allowing the arytenoid mucosa to vibrate against the residual epiglottis or base of the tongue.

Subtotal laryngectomy procedures remained substantially unchanged from the 1970s, until Rizzotto et al. (2006)<sup>5</sup> reviewed the tracheohyoidopexy and tracheohyoido-epiglottopexy techniques. By observing the importance of the functional cricoarytenoid unit (unlike Authors such as Serafini and Mayer who previously used similar techniques but overlooked this aspect), these Authors performed subtotal laryngectomies even in unilateral hypoglottic tumours: the tracheohyoidopexies described in the paper by Rizzotto et al. involved the removal of significant portions of cricoid on the tumour side, but preserved at least one arytenoid unit, the portion of cricoid below, the superior laryngeal nerve, lateral internal branch (plus, the recurrent laryngeal nerve), and by performing the reconstruction directly between the trachea and hyoid bone (with or without the residual epiglottis): in their paper, they reported functional results comparable with conventional subtotal procedures.

Those who work in the laryngeal surgery field constantly have to manage the deglutition and phonatory rehabilitation of laryngectomised patients, fully aware of all the medical, nutritional, psychological, organisational and even economical issues that face both patients and medical practitioners. It goes without saying that the greater the efforts to spare the larynx, the more diffuse conservative laryngeal surgery techniques and the more important the vocal and deglutition rehabilitation techniques become. The purpose of this Round Table is, therefore, to focus attention on the issues of post-laryngectomy speech and swallowing rehabilitation, in the light of contemporary surgical techniques, which primarily aim to spare the organ and respect function and quality of life.

## References

- Staffieri M, Serafini I. *La riabilitazione chirurgica della voce e della deglutizione dopo laringectomia totale*. Relazione Ufficiale Atti del XXIX Congresso Nazionale AOOI, 1976.
- Mayer EH, Reider W. *Technique de laringectomie permettant de conserver la permeabilité respiratoire (la crico-hyoido-pexie)*. Ann Otolaryngol 1959;76:677-81.
- Piquet JJ, Desaulty A, Delacroix G. *La crico-hyoido-pexie technique opératoire et résultats fonctionnels*. Ann Otolaryngol Chir Cervicofac 1974;91:681-6.
- Labayle J, Bismuth R. *La laryngectomie totale avec reconstruction*. Ann Otolaryngol Chir Cervicofac 1971;88:219-28.
- Rizzotto G, Succo G, Lucioni M, et al. *Subtotal laryngectomy with tracheohyoidopexy: a possible alternative to total laryngectomy*. Laryngoscope 2006;116:1907-17.

Address for correspondence: Dr. L. Presutti, U.O.C. Otorinolaringoiatria, Azienda Ospedaliero-Universitaria di Modena, via del Pozzo 71, 41100 Modena, Italy.

# Anatomy and Physiology of the operated larynx

## *Anatomo-fisiologia della laringe operata*

E.M. CUNSOLO

ENT Department, University Hospital of Modena, Modena, Italy

Correct knowledge of the anatomy and physiology of the operated larynx is crucial to the success of functional laryngeal cancer surgery. A fundamental distinction must be made between procedures involving the removal, to a greater or lesser extent<sup>1</sup>, of the vocal fold and those that not only alter the endolaryngeal soft tissues, but also entail the reductive remodelling of the laryngeal framework and repositioning of the neolarynx within the neck.

In addition to the morphology of the neolarynx, other pre-existing and/or post-surgical anatomic and functional elements that can prove decisive to the success of the procedure must also be considered. Of these, the most important are the presence of spinal cord disease, laryngopharyngeal reflux (LPR), any upper respiratory and digestive tract disorders following radiotherapy, salivary flow alterations and, last but not least, the patient's psychological conditions.

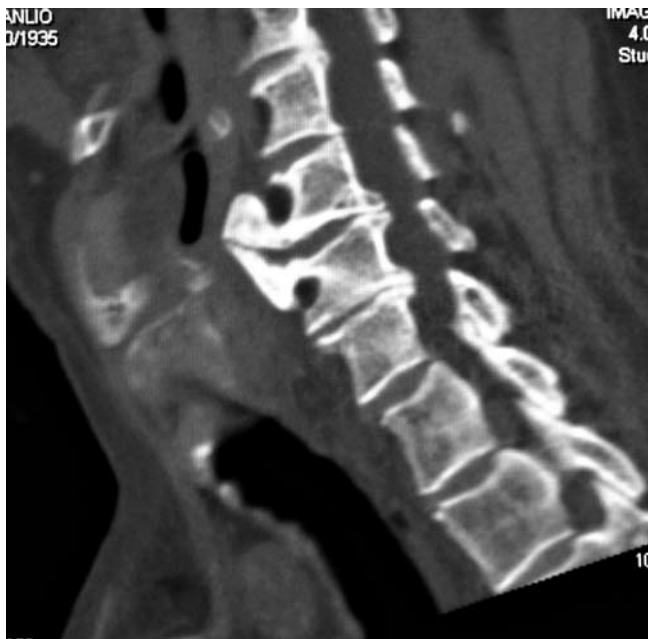
Cervical spinal disease can take the form of cumbersome bone spurs on the vertebral bodies in severe spinal arthritis or concomitant Diffuse Idiopathic Skeletal Hyperostosis (DISH). These conditions must be taken into consid-

eration when planning surgery and be sometimes treated surgically during the laryngeal cancer procedure (Fig. 1). Bruno et al.<sup>2</sup> identified a number of quantitative parameters, visible on pre-operative computed tomography (CT) scans, that can be useful in pinpointing the position of the neolarynx in the neck following crico-hyoido-epiglottopexy (CHEP), of prognostic importance as far as concerns post-operative functional recovery.

The role of LPR in glottic tissue repair processes and, more generally, in all procedures involving laryngeal and/or laryngotracheal reconstructions, deserves special mention. The negative influence of LPR in glottic repair processes has been analysed in studies on animals and, more recently, in clinical studies on humans. In animal studies<sup>3</sup>, irrigation using hydrochloric acid with a pH of 3 and pepsin was administered for 4 or 8 weeks after vocal cord stripping. This group of animals experienced delayed healing, intense inflammation, epithelial erosion and formation of granular tissue, with distant sequelae that evolved into rigid scar tissue, with significant dense collagen deposition. This immediate and delayed tissue damage was evaluated quantitatively and showed a clear statistical significance compared to the control group receiving sterile saline solution irrigations.

In a recent clinical study<sup>4</sup>, healing after vocal cord surgery for benign tumours was compared between a control group (50 patients) and a group of 120 patients with LPR, documented with 24-hour dual probe pH monitoring and whose clinical severity was evaluated using subjective parameters, (RSI: Reflux Symptom Index) and objective laryngeal parameters (RFS: Reflux Finding Score). 50% of patients with LPR were randomised to receive pre- and post-operative proton pump inhibitor (PPI) treatment and the anatomical and functional results were evaluated over a one-year follow-up period. The results obtained demonstrated a significant delay in vocal cord re-epithelisation processes and the persistence of high RSI and RFS scores in the untreated patients. This clinical finding confirms the importance of LPR and its pre- and post-operative treatment, with adequate doses of PPI.

The negative impact of LPR on repair processes, following laryngeal surgery, is related to the extent of laryngeal demolition. In one study on rabbits, subject to laryngotracheal reconstruction<sup>5</sup>, the Authors observed intense mucosal inflammation, with necrosis of the underlying car-



**Fig. 1.** Pre-operative CT: patient with laryngeal cancer (indication to SCL-CHEP) and DISH syndrome. Treatment of this latter condition takes place at the same time as the laryngeal cancer operation.

tilage in animals receiving hydrochloric acid and pepsin irrigations. These alterations were more marked in the group receiving irrigations with pH of 4 hydrochloric acid compared to those in the group receiving that with a pH of 1.5. Moreover, this latter group of animals was less prone to coughing, when evaluated quantitatively (using the Cough Response Scoring System), compared to those irrigated with HCl with a pH of 4. The pathophysiological basis underlying these events can probably be attributed to the immediate swallowing reflex that is activated when the pharyngo-laryngeal mucosa comes into contact with a strongly acidic solution. This swallowing reflex is so fast and efficacious that it prevents acid micro-aspirations in the lower respiratory tract and restricts the mucosal damage caused when it comes into contact with the areas of the larynx subject to reconstruction. Despite the limits related to the artificiality and complexity of the trial model, this finding has important clinical repercussions. It underlines the detrimental effect of slightly acidic and/or non-acidic LPR and the decisive importance of the sensitive innervation of the hypopharynx and larynx, which is able to activate an effective coughing reflex, the afferent branch of which is the internal branch of the superior laryngeal nerve. Another “extralaryngeal” aspect that can prejudice functional recovery after major laryngeal surgery and that merits closer investigation is the patient’s psychological conditions and related anatomic and functional conditions, represented by the cortical control of laryngeal functions, in general, and deglutition, in particular.

The latest studies using functional magnetic resonance imaging techniques (fMRI), have confirmed the complexity of neuronal control of deglutition, defining a highly coordinated “swallowing neural sensory-motor network” in which different cortical areas and encephalic and brainstem structures interact to provide a safe and effective transport of the liquids and solid foods from the lips to the stomach. In 2001, Martin et al. published a report on a fundamental study, conducted on healthy volunteers<sup>6</sup>, for the definition of the cortical areas activated to promote and coordinate the act of deglutition. The underlying assumption was to make a distinction between “spontaneous” salivary deglutition (automatic swallowing) and deglutition controlled by a voluntary action (volitional swallowing), which, in turn, can be broken down into voluntary salivary deglutition and voluntary swallowing of a bolus (liquid or solid). In the study of Martin et al., healthy volunteers were also evaluated by fMRI-4T in three different swallowing “modes”: 1. Naïve saliva swallowing; 2. Voluntary saliva swallowing: performed with a frequency of one swallow a minute; 3. Water bolus swallowing: swallowing of a fixed quantity (3 ml) of water administered once a minute, through a tube in the mouth. The synchronism of the cortical events and acts of deglutition was guaranteed by recording laryngeal excursions. The still-valid results of this landmark study can be summarised as follows: 1. All swallowing involves

cortical activation, even automatic deglutition, which represents the quantitatively predominant event; 2. Both types of deglutition involve several anatomically and functionally separate areas of cortex, with a different pattern during automatic, compared to voluntary, swallowing; 3. Volitional swallowing of both saliva and water boli are associated with a pre-eminent activation of the caudal portion of the cingulate gyrus; 4. There are pre-eminent and more constant foci of cortical activation, which are activated in both types of swallowing, represented by the precentral lateral gyrus (Brodmann areas 4 and 6), the post-central lateral gyrus and the right insula.

Perhaps the most surprising aspect of this study is the documentation of the cortical events that occur at the same time as the most elementary act of deglutition, the automatic swallowing of saliva, termed, on account of its basic nature, “naïve saliva swallowing”. Not only is it invariably associated with cortical activation, but, in this context, it also activates the “nobler” motor areas, such as the premotor cortex (Brodmann area 6) and, above all, the precentral lateral gyrus, area 4, which includes the primary motor cortex, which is, therefore, indicated as M1. When applied to the clinical setting, these notions allow a broadening of the concept of post-operative dysphagia following major tumour surgery on the upper respiratory tract, intended not merely as an alteration of deglutition for eating and drinking (voluntary bolus swallowing), but also in the broader basic concept of controlling the physiological salivary flow, managed by “naïve saliva swallowing”. Consequently, in laryngeal tumour surgery, a key role is played by all the surgical measures adopted to preserve an adequate “pharyngolaryngeal wall” and the integrity of sensory innervation, as well as the recognition and adequate treatment of post-operative salivary flow disorders<sup>7</sup>.

In recent years, a number of studies have been published on the “swallowing cortical network”<sup>8</sup>, with the aim of applying this knowledge to clinical practice, both in patients whose swallowing disorders are secondary to neurological damage and whose anatomical “damage” is in the peripheral laryngopharynx, as occurs following major functional laryngeal tumour surgery. In these patients, there is a post-surgical alteration of the laryngopharyngeal structures, with preserved integrity of the central neurological network. Precisely on account of the importance of cortical control of all types of swallowing, this network can be functionally altered due to the patient’s post-operative psychological conditions. A recent study on healthy volunteers, conducted by Palmer et al.<sup>9</sup>, compares the dynamics of the oral preparation phase, the oral and pharyngeal stage of solid bolus swallowing, when it takes place automatically or following a voluntary act of deglutition, performed after completion of the oral preparation phase and triggered by a command given by the investigator. The overall dynamics of the initial phases of deglutition are more efficacious when automatic and not

commanded, and is slower during controlled swallowing (larger number of masticatory acts, slower propulsion, stoppage of the bolus at the valleculae). The pathophysiological implications of this observation are easily identifiable and explain the organisational complexity of the neuronal network that governs spontaneous deglutition.

On a practical level, the points raised previously highlight the importance of early rehabilitation of the swallowing function in patients after major laryngeal surgery, with the triple aim of optimising the dynamics of the neolarynx, obtaining a true reprogramming of the neuronal network through phenomena of neuroplasticity<sup>10</sup> and a minimisation of the effects of volitional control, which can be counterproductive to correcting deglutition dynamics.

If, as previously mentioned, there has been a rapid expansion in the definition of the central neuronal network controlling laryngeal functions, no less significant is the quantitative and qualitative evolution in the knowledge of motor and sensory control of the laryngopharyngeal system, which has led to the definition of the concept of the “neurosensory compartmentalisation” of the larynx. All the areas of intrinsic laryngeal muscle have been defined in relation to their muscle fibre population at structural, ultrastructural and biomolecular levels, intra-muscular distribution of nerve fibres, density of neuromuscular plaques and, consequently, in the amplitude of the motor units. The most extensively studied muscular district is that of the thyroarytenoid muscle, and, specifically, its internal component, or vocal muscle<sup>11</sup>.

More recently, the same attention has been dedicated to the definition of the pharyngeal constrictor muscles<sup>12</sup>. This activity has led to the identification of a sophisticated “neuromuscular compartmentalisation” that, as for the intrinsic muscles of the larynx, varies significantly with age. The pharyngeal constrictors are divided into two distinct and functionally separate layers: the slow inner layer (SIL), innervated by the glossopharyngeal nerve (IX) and the fast outer layer (FOL), innervated by the vagal nerve (X). This anatomical and functional layering of the constrictor muscles is only present in humans, it appears around two years of age and disappears after the age of 70. The SIL is made up of muscle fibres with myosin heavy chain (MHC) isoforms of the slow-tonic and a-cardiac type. These MHC isoforms are highly specialised in tonic muscle contraction and are linked to the need of controlling deglutition when in an erect position, with a low aerodigestive crossroads, typical of adult. The FOL, with fast tonic MHC and vagal innervation, on the other hand, is specialised in the peristaltic food bolus propulsion. Once again, these considerations lead us to consider the aerodigestive crossroads as an integrated functional structure with synergic, overlapping vagal and glossopharyngeal sensory-motor innervation. On a practical level, this calls for surgical respect of all those structures not involved in the neoplastic process, including all mucosal, muscular, nervous and vascular components.

The other particularly current issue, in the functional anatomy of the larynx, is what we refer to as the “cellular physiology of the larynx”<sup>13</sup>. This area focuses on connective cells and the intercellular substance they produce, as concerns both its fibrous (elastin and collagen) and amorphous components. Familiarity with these aspects of cell physiology has allowed a better understanding at molecular level of the repair processes that take place after anatomical cord damage and their “undesired” evolution towards cordal scarring.

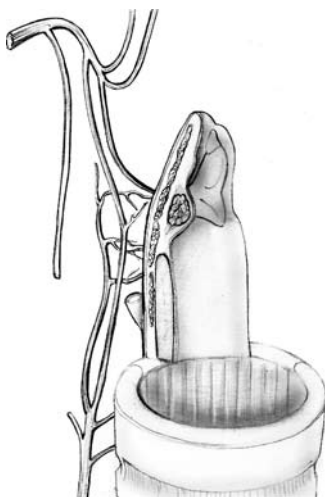
Recently, Hirano et al.<sup>14</sup> conducted a study on cord tissue repair processes in patients undergoing vocal cord surgery of various types. The purpose of the study was the molecular quantification of the various components of the extracellular matrix: collagen, elastin, hyaluronic acid, fibronectin and decorin. The results showed a great variability in post-surgical outcomes, inside which different behaviours can be identified for collagen and decorin and for elastin, hyaluronic acid and fibronectin. The post-operative collagen and decorin content is related to the depth of the surgical resection of the cords and subsequent scarring process. The greater the depth of the resection, the greater the deposition of thick, disorganised collagen fibres, especially in cases of post-operative radiotherapy. The opposite occurs for decorin, which is preserved in more superficial cordectomies, but tends to drop in deeper procedures. Decorin is a small-chain proteoglycan that governs the collagen fibrils, preventing them from forming large bundles and thus avoiding the formation of dense scar tissue. Decorin is, physiologically, primarily present in the more superficial layers of the lamina propria, which explains the histological findings reported. Deposition of the other components of the extracellular matrix, such as elastin, fibronectin and, above all, hyaluronic acid, on the other hand, occurs regardless of the depth of vocal cord resection and their content in the post-operative cord tissue is governed by highly variable, individual factors. There are many practical repercussions of the elements that came to light in this study, all of them of great clinical importance, making the indications for phoniatic and/or voice surgery after endoscopic cordectomy, even in the more superficial procedures, an issue of great current interest.

However, there is no doubt that the post-operative redefinition of the operated larynx occurs above all following procedures that reduce the laryngeal framework. At a pathophysiological level, it is correct to define the type of laryngectomy, indicating the most caudal anatomic element above which the neolarynx is reconstructed: hence the definition of supraglottic horizontal laryngectomy (SHL), supracricoid laryngectomy (SCL) (crico-hyoido-epiglottopexy [CHEP], crico-hyoidopexy [CHP]) and supratracheal laryngectomy (STL). It goes without saying that procedures requiring the anatomical and functional redefinition of the operated larynx are those entailing the resection of the glottic level of the cords, the natural sphincter of the larynx, calling for the surgical reconstruc-

tion of a “neoglottis”. We will, therefore, describe the basic anatomy and physiology of the neolarynx after SCL and STL procedures.

The anatomical and physiological foundation of this kind of surgery is the cricoarytenoid unit (CAU). This structure has both a “classic” and an “updated” definition.

The classic definition was developed in 1992, by J.J. Piquet et al.,<sup>15</sup> the original version of which is provided below: “L’unité crico-aryténoïdienne se compose d’un squelette fibro-cartilagineux constitué par le cartilage cricoïde ainsi que d’un ou deux cartilages aryténoïdes articulés entre eux. Cette articulation ne peut rester fonctionnelle que dans la mesure où les muscles crico-aryténoïdiens postérieur, crico-aryténoïdiens latéraux et inter-aryténoïdiens parfois, sont respectés avec leur innervation, leur vascularisation ainsi qu’un plan muqueux de couverture à préserver”. The fundamental aspect of this definition of CAU lies in the specification not so much of its anatomical appearance, but rather its functional appearance that represents the essence of the larynx only if it is perfectly intact as regards to its complex cricoarytenoid joint, its muscular apparatus, sensory-motor innervation and mucosal coating. This “classical” concept of the CAU has been replaced by a more “extreme” version, with a graphic schematisation that graced the cover of the October 2006 issue of *Laryngoscope* (Fig. 2). Once again, we provide the original definition: “one cricoarytenoid unit (half posterior cricoid plate and one arytenoid)”<sup>16</sup>. Reducing the framework makes it all the more urgent to maintain intact the function of all components of the CAU and stresses the second fundamental element of the physiological anatomy of the neolarynx, the ‘position’ element. Here, it becomes necessary to introduce the second “hinge” definition of the issue, the definition of “neoglottis”, which we will borrow, once again, from J.J. Piquet: “La néo-glote est constituée d’une partie antérieure musculaire basilinguale (à laquelle s’ajoute l’épiglotte dans une CHPE) et d’une partie postérieure correspondant à une ou deux unités crico-aryténoïdiennes... La situation de la néo-



**Fig. 2.** CAU: Current concept. Articular, neuromuscular, vascular and mucosal integrity of the cricoarytenoid complex is essential. The continuity of the cricoid cartilage is not necessary.



**Fig. 3.** Diagram of the neoglottis. The front half comprises the base of the tongue, the rear half by at least one efficacious CAU.

glotte est particulière car haute ou additale, située dans le plan de la margelle laryngée”. This defines the concept of the “neoglottis”, a circular structure, the true upkeeper of neolaryngeal functions: respiratory function, speech function and deglutition function. The neoglottis is, therefore, a circular structure in which the rear 180° are, schematically, represented by at least one efficient CAU, whereas the anterior 180° are represented by the base of the tongue, overlapped, when applicable, by the residual suprahyoid epiglottis (Fig. 3). The functional competence of this “ring” stems not so much from the anatomical-functional integrity of each of its components, but rather, to an equally important extent, from the juxtaposition of the front half with the back half. This is what makes “position” the second requisite of an optimised CAU. These elements form the grounds for the success of major functional laryngeal surgery, and are linked to the rehabilitation and/or surgical work performed to correct functional failures.

The first anatomical element of the “position” of the neoglottis is the lifting of the residual larynx, in a cranial direction, towards the base of the tongue. For this, the reconstruction must be stable, which is obtained by overlapping and positioning the concave portion of the hyoid body on top of the cricoid or, in the case of STL, the upper rings of the trachea. This also guarantees a correct alignment of the reconstruction in relation to the respiratory lumen, the essential condition for natural breathing. Once the structural correctness of the mutual relationships between the components of the neoglottis has been guaranteed, the performance of respiration, speech and deglutition functions will require a specific dynamic pattern for each of the three functions, that is based, as mentioned previously, on a correct neoglottis neuromuscular apparatus and a good degree of cricoarytenoid joint freedom.

*Respiratory function* requires an adequate lumen along the whole reconstructed respiratory tract and an efficacious opening of the residual larynx. This function is assigned to the posterior cricoarytenoid muscle, innervated by the inferior or recurrent laryngeal nerve. The contraction of this muscle, considering its insertion of the muscular apophysis of the arytenoid and the degrees of freedom of the cricoarytenoid joint, will produce a multiplane arch movement of the body and vocal process of the arytenoid, in an upwards, outwards and backwards direction. This spatially complex movement, more simply defined as ab-

ductory, will bring the arytenoid body and vocal process from an inferomedial starting position to a superolateral end position, thus widening the respiratory lumen.

The phonatory and deglutition functions both require the competence of a neoglottic sphincter. This *neoglottic sphincter* will invariably be constituted by the juxtaposition of the CAU to the rear and the base of the tongue to the front. The action of the front half of the neoglottic sphincter will be guaranteed by the retropulsion of the base of the tongue, downwards and backwards. In SCL with CHEP procedures, this sphincter will be assisted by the presence of the residual epiglottis, to give it a correct position, making it possible to follow the movements of the base of the tongue, without, simultaneously representing an obstacle for the respiratory lumen.

As mentioned previously, the competence of the rear half of the neoglottic sphincter depends on the CAU and is based on a complex cricoarytenoid movement, which occurs with a synergical action, of recorrential competence, of the lateral cricoarytenoid, posterior cricoarytenoid and, when both arytenoids are present, interarytenoid muscles. The contraction of the lateral cricoarytenoid muscle tends to pull the muscular apophysis downwards and forwards, causing the arytenoid to move over the cricoid so that the vocal apophysis and the arytenoid body draw an arc downwards, inwards and forwards. As the lateral cricoarytenoid muscle contracts, the posterior cricoarytenoid muscle relaxes, tilting the arytenoid body forwards. When present, the simultaneous contraction of the interarytenoid muscle produces a tighter action of the posterior sphincter, thus favouring the meeting of the anterior aspects of the arytenoids. These complex articular and neuromuscular dynamics produce a multiplane movement of the arytenoid that draws a quarter- or semi-circular arc with an internal concavity moving forwards, downwards and inwards. On laryngoscopic observation, this complex dynamic can be schematically split into two essential components, for which the original French names are used: “*le salut aryténoïdienne*” and “*le rideau de scène*” (J.J. Piquet) (Fig. 4).

“*Le salut aryténoïdienne*”: describes the vertical component of the arytenoid body, which tilts forwards and downwards, towards the base of the tongue. This causes the posterior cricoarytenoid muscle to relax.

“*Le rideau de scène*”: describes the horizontal component, favoured by the lateral cricoarytenoid muscle, which brings the arytenoid into medial contact with the contralateral, if present, or up to the contralateral laryngeal wall, in the case of a single residual arytenoid. It should be a true “curtain falling”, with one or two curtains.

Whereas the above description refers to the fundamental mechanism that guarantees neoglottic competence, the dynamics will be different in the occlusion mechanisms for phonation and deglutition.

In *phonation*, the retropulsion of the base of the tongue

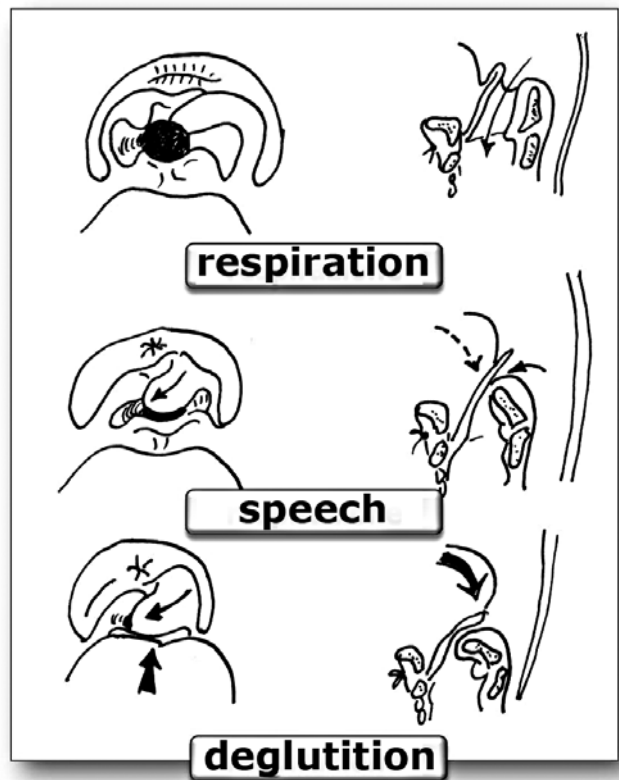


Fig. 4. Dynamics of the neoglottis in the 3 fundamental functions. The arytenoid excursions (“*le rideau de scène*”) are shown on the right hand side. The dynamics of the neoglottis on the vertical plane: retropulsion of the base of the tongue and “*le salut aryténoïdienne*” is shown on the left.

has the essential purpose of allowing glottic competence, whilst the active participation of the CAU is predominant. Piquet defines this dynamic action of the neoglottic sphincter as: “*mécanisme léger*”.

In *deglutition*, on the contrary, the retropulsion of the base of the tongue is active, to allow a real tightening of the neoglottis. Consequently, it is a “*mécanisme lourd*”.

*Neoglottic vibration*: So far, we have described the aspects of the neoglottic “framework” that do not take into consideration the behaviour of the mucosa, the vibration of which is essential in allowing the neoglottic sphincter to produce a “neovoice”. The phonatory vibrations of the mucosa involve the arytenoid hoods and the other elements of the neoglottis, particularly in the case of SCL-CHEP, when the vibratory pattern will also involve the mucosa of the epiglottis and the piriform fossa, as an element of the neo-aryepiglottic folds. Recently, Saito et al.<sup>17</sup> proposed a classification of the mucosal vibratory patterns of the neoglottis after SCL-CHEP. The Authors defined 3 areas of mucosal vibration, defined: Area A (arytenoid/s); Area E (epiglottis); Area S (piriform sinus mucosa). The vibratory patterns encountered are: Type A; Type S; Type AS; Type AE and Type AES.

This proposal responds to the currently particularly urgent need to identify classification systems to evaluate the functional results of functional laryngeal cancer sur-



gery<sup>18</sup>, due partly to the enormous progress achieved in video-laryngoscopy techniques.

## Conclusions

The topic of the anatomy and physiology of the operated larynx is undoubtedly complex and multifactorial, cur-

rently dealt with in the literature of various disciplines and, therefore, "dispersed" but worthy of further speculative and clinical exploration.

These notes illustrate how the functional outcome following laryngeal cancer surgery relies on respecting all the elements in that constellation of factors that permit a minimal neolarynx anatomic and functional dignity.

## References

- <sup>1</sup> Remacle M, Van Haverbeke C, Eckel H, et al. *Proposal for revision of the European Laryngological Society classification of endoscopic cordectomies*. Eur Arch Otorhinolaryngol 2007;264:499-504.
- <sup>2</sup> Bruno E, Napolitano B, Sciuto F, et al. *Variations of neck structures after supracricoid partial laryngectomy: A multislice computed tomography evaluation*. ORL 2007;69:265-70.
- <sup>3</sup> Jong-Lyel Roh JL, Yoon YH. *Effect of acid and pepsin on glottic wound healing - A simulated reflux model*. Arch Otolaryngol Head Neck Surg 2006;132:995-1000.
- <sup>4</sup> Kantas I, Balatsouras DG, Kamargianis N, et al. *The influence of laryngopharyngeal reflux in the healing of laryngeal trauma*. Eur Arch Otorhinolaryngol 2009;266:253-9.
- <sup>5</sup> Carron JD, Greinwald JH, Oberman JP, et al. *Simulated reflux and laryngotracheal reconstruction - a rabbit model*. Arch Otolaryngol Head Neck Surg 2001;127:576-80.
- <sup>6</sup> Martin RU, Goodyear BG, Gati J, et al. *Cerebral cortical representation of automatic and volitional swallowing in humans*. J Neurophysiol 2001;85:938-50.
- <sup>7</sup> Bomeli SR, Desai SC, Johnson JT, et al. *Management of salivary flow in head and neck cancer patients - A systematic review*. Oral Oncol 2008;44:1000-8.
- <sup>8</sup> Michou E, Hamdy S. *Cortical input in control of swallowing*. Curr Opin Otolaryngol Head Neck Surg 2009;17:166-71.
- <sup>9</sup> Palmer JB, Hiimeae KM, Matsuo K, et al. *Volitional control of food transport and bolus formation during feeding*. Physiol Behav 2007;91:66-70.
- <sup>10</sup> Ludlow CL, Hoit J, Kent R, et al. *Translating principles of neural plasticity into research on speech motor control recovery and rehabilitation*. J Speech Lang Hear Res 2008;51:S240-58.
- <sup>11</sup> Cunsolo EM, Marchioni D, Di Lorenzo G, et al. *Attualità in tema di anatomo-fisiologia e biomeccanica della laringe*. In: Magnani M, Ricci Maccarini A, Füstös R, editors. *La Videolaringoscopia*. Relazione Ufficiale XXXII Convegno Nazionale di Aggiornamento AOOI, Pollenzo (TO); 16-17 ottobre 2008.
- <sup>12</sup> Mu L, Sanders I. *Neuromuscular specializations within human pharyngeal constrictor muscles*. Ann Otol Rhinol Laryngol 2007;116:604-17.
- <sup>13</sup> Cunsolo EM, Casolino D, Cenacchi G. *La fisiologia cellulare delle corde vocali*. In: Casolino D, editor. *Le disfonie: fisiopatologia, clinica ed aspetti medico-legali*. Relazione Ufficiale del LXXXIX Congresso Nazionale SIO, San Benedetto del Tronto, 22-25 maggio 2002. Pisa: Pacini Editore; 2002, p. 64.
- <sup>14</sup> Hirano S, Minamiguchi S, Yamashita M, et al. *Histologic characterization of human scarred vocal folds*. J Voice 2009;23:399-407.
- <sup>15</sup> Piquet JJ, Chevalier D, Lacau-StGuily J, et al. *Après exérèse horizontale glottique, sus-glottique, glosso-sus-glottique et hémipharyngolaryngée*. In: Traissac L, editor. *Réhabilitation de la voix et de la déglutition après chirurgie partielle ou totale du larynx*. Société Française d'Oto-Rhino-Laryngologie et de Pathologie Cervico-Faciale. Paris: Arnette; 1992, p. 173-92.
- <sup>16</sup> Rizzotto G, Succo G, Lucioni M, et al. *Subtotal laryngectomy with tracheohyoidopexy: a possible alternative to total laryngectomy*. Laryngoscope 2006;116:1907-17.
- <sup>17</sup> Saito K, Araki K, Ogawa K, et al. *Laryngeal function after supracricoid laryngectomy*. Otolaryngol Head Neck Surg 2009;140:487-92.
- <sup>18</sup> Marioni G, Marchese-Ragona R, Ottaviano G, et al. *Supracricoid laryngectomy: is it time to define guidelines to evaluate functional results? A review*. Am J Otolaryngol 2004;25:98-104.

Address for correspondence: Dr. E.M. Cunsolo, U.O.C. Otorinolaringoiatria, Azienda Ospedaliero-Universitaria di Modena, via del Pozzo 71, 41100 Modena, Italy.

# Speech therapy rehabilitation

## *La riabilitazione logopedica*

M.P. LUPPI, F. NIZZOLI, G. BERGAMINI, A. GHIDINI, S. PALMA  
ENT Department, University Hospital of Modena, Italy

The speech therapy rehabilitation programme starts with diagnosis and continues during hospitalisation and after the patient's discharge.

The distance from the rehabilitation centre can be an unfavourable element for the correct application of the whole protocol and the achievement of optimal functional results, particularly from a vocal point of view.

Psychological support is important for controlling and respecting the anxiety and depression that arises following the diagnosis of a tumour. It is, therefore, essential that the speech therapist is able to meet the patient before the procedure in order to establish that relationship of trust which is fundamental for rehabilitation programme compliance. During the pre-operative meeting, the speech therapist will explain to the patient the functional issues connected with the procedure and the re-education strategies used to restore compromised function.

Adequate post-surgical rehabilitation is essential for all functional cancer surgery that, with the exclusion of cordectomies, in which it is conducted on a purely outpatient basis, involves a phase during hospitalisation and a subsequent post-discharge, outpatient or day hospital, phase.

### **Cordectomies**

Post-cordectomy speech therapy is aimed at recovering the voice and to be fully efficacious, it must favour the meeting of the cord and neocord, to prevent disadvantageous non-spontaneous compensations. It is precisely for this reason that re-education starts early and, in any case, after full surgical healing.

In cases in which non-optimal vocal compensations and/or markedly dysfunctional attitudes are present, work will focus on eliminating these problems before adopting the best phonatory mode.

In those cases in which the new anatomical laryngeal situation does not make it possible to achieve physiological cord-neocord compensation<sup>1-4</sup>, phonatory exercises will aim to strengthen the false cord or arytenoepiglottic (sphincteric) voice, which will, in any case, allow the cordectomy patient to obtain enough voice for normal interpersonal relationships.

The first step is always to achieve a correct respiratory dynamic (costo-diaphragmatic breathing) and good pneumoarticular coordination<sup>5</sup>.

To obtain a voice produced in the glottis (cord-neocord), vocal sounds (vowels and syllables with surd and sonant occlusive phonemic components) are used at acute pitch but moderate intensity constantly using laryngeal manipulation which will favour compensation by the healthy vocal cord. This will be followed by vocal exercises to prolong and strengthen the sound through the repetition of syllables (surd and sonant occlusives), monotonous variable combined vowels, pitch changes with vowels and syllables, disyllabic words, reading of words, sentences and stories.

In those cases in which one of the other vocal compensations is required, we use exercises with lowered head facilitating postures, vocal sounds with a low pitch and moderate intensity that are prolonged on nasal phonemes and on the vibrating phonemes, which can be proposed either individually or combined with sonant or surd velar occlusives. After which, the patient will practice, by reading sentences and short stories, to improve prosody, which is always lacking in these compensations and especially in the sphincteric voice.

### **Horizontal functional laryngectomies**

In supraglottic horizontal laryngectomy (SHL), the residual sphincteric structure is represented by the glottic level (vocal cords and arytenoids). Consequently, at the end of re-education, in the absence of functional deficits of these structures, the three laryngeal functions are optimally restored.

Glottic horizontal laryngectomy (GHL) involves the resection of the glottic level, leaving the false cords, arytenoids and aryepiglottic folds.

Generally, there are no swallowing problems after therapy, due to the conservation of the two sphincteric structures (epiglottis and false cords), however the voice will be rough and have a low pitch, as it is generated by the vibrations of the false cords.

### **Subtotal laryngectomies**

In subtotal laryngectomies, the sphincteric function, the basis for the protection of the airways and for phonation, is represented by the cricoarytenoid unit, in which there is a dynamic opposition between the arytenoids and the epiglottis (cricohyoidoepiglottopexy or CHEP, tracheohy-

oidoepiglottopexy or THEP) or the base of the tongue (cricohyoidopexy or CHP and tracheohyoidopexy or THP)<sup>6</sup>. The deglutition and phonatory abilities of these patients rely on the perfect function of the neoglottis and the conservation of mucosal sensitivity as well as the patient's ability to learn new swallowing and speech strategies.

The same rehabilitation techniques are used for all functional laryngectomies, albeit with a number of variations and customisations.

Before discussing post-operative rehabilitation training, we must stress the importance of giving these patients adequate psychological support, to avoid excessive anxiety and depression, which may negatively affect their compliance and confidence in a good rehabilitation outcome.

During the first meeting, the patient should be given detailed information about the procedure and about their post-operative anatomic and functional situation: they will temporarily have to breathe through a tracheotomy tube and feed through a nasogastric (NG) tube, or, in certain cases, through a percutaneous endoscopic gastrostomy (PEG). The speech therapist will also discuss the re-educational methods to be used for deglutition and phonatory recovery, attempting to instil a calm and trusting state of mind towards the procedure and post-operative recovery<sup>7,8</sup>.

### Rehabilitation objectives and schedule<sup>7,9</sup>

The purposes of re-education are: the activation of the deglutition mechanisms, arytenoid mobilisation and activation of arytenoid mucosal vibration.

These objectives are achieved by following the rehabilitation steps:

- on the 5<sup>th</sup> post-operative day, if the cuffed tracheostomy tube has been replaced with a fenestrated one, the breathing exercises can commence;
- on the 6<sup>th</sup> post-operative day, arytenoid mobilisation exercises and mouth exercises in preparation for swallowing start;
- on day 7, the patient is taught the facilitating deglutition mechanism and tests will be performed swallowing both saliva and jelled water;
- on day 8, the patient will be expected to swallow a creamed meal administered directly with the speech therapist's help;
- in the days that follow, different foods, with different textures will be introduced, up to the introduction of water, the most difficult manoeuvre.

The presence of the NG tube can hamper rehabilitation as it gives the feeling of a foreign body and cricoarytenoid ankylosis, due to the position of the tube on the joint. Once the NG tube and tracheostomy tube have been removed (discharge), outpatient vibration and resonance exercises will start<sup>10,11</sup>.

We will now analyse, in detail, the various phases of rehabilitation, schematically discussing the various speech therapy techniques.

## Breathing exercises

These are performed in order to achieve correct costo-diaphragmatic breathing, allowing the airflow to pass through the natural respiratory tract, favouring a more rapid reabsorption of the post-operative oedema.

They are initially performed with the tracheostomy open, then later by closing it with a finger.

### Costo-diaphragmatic breathing exercises:

- slow inspiration through the nose, slow expiration through the mouth;
- slow inspiration through the nose, expiration in 3, 4, 5 blows, through the mouth;
- slow inspiration through the nose, fast expiration through the mouth;
- slow inspiration through the nose, fast expiration with the articulation of an aphonous voice (preparatory exercise for arytenoid mobilisation)<sup>1,9,5</sup>.

### Muscle training exercises:

- exercises to control the head and neck, making rotating movements, bending forwards, to the right, left and in extension;
- shoulder movements: raising and lowering, rotating one way and then the other, lifting the arm to the side and to the front;
- lip exercises: protrusion and stretching, kissing;
- tongue exercises: sideways movements, sticking out the tongue, downwards, upwards, right and left, outwards rotation in one direction, then the other, pressing against the inside of the cheeks, rotations in the oral vestibule, brushing the palate with an antero-posterior movement<sup>7,11</sup>.

## Pharyngeal stimulation exercises

The aim of these exercises is to stimulate contraction of the pharynx and they consist in causing the vomiting reflex using a cold mirror or tongue depressor. If no evident reaction is observed when the palatine veil is stimulated, the palatine pillar area can be stimulated<sup>7,9</sup>.

## Laryngeal lift stimulation exercises

Following the procedure, the relationship between laryngeal lifting and opening the mouth of the oesophagus is altered and the exercises aim to restore this situation. However, these lifting manoeuvres are only partly possible, due to the presence of the tube<sup>9,10</sup>.

## Arytenoid mobilisation exercises

These are used to obtain the best neolaryngeal closure and to favour vibration of the arytenoid mucosa.

- Rasping: the patient is seated, the tracheostomy tube closed with a finger, and he/she must breathe in slowly then give the loudest rasp possible, with the mouth only;
- Rasp with vowel: the patient is asked to produce a rasp followed by a vowel, starting with /a/, then /e/ and /o/, and then trying with /i/ and /u/<sup>19 11</sup>.

## Swallowing exercises

The patient practices facilitating swallowing, in the following sequence:

1. closing the tracheostomy tube with a finger;
2. short nasal inspiration;
3. pause in apnoea during which the patient swallows, thrusting the tongue hard against the palate, as far back as possible and holding this muscular contraction for a few seconds after swallowing;
4. abrupt release of air from the mouth, with the possibility of expelling any food fragments remaining in the neolarynx or hypopharynx.

This mechanism is initially performed using:

- *facilitating postures*: the patient is seated with the head thrust forwards and the trunk bent downwards; head, trunk and neck must all be on the same plane, parallel to the floor. In the event of laterocervical stripping and removal of one arytenoid, the patient is asked to turn his/her head to the side of the residual arytenoid;
- *facilitating manoeuvre*: the therapist puts one hand behind the neck of the seated patient and places the other resting on his/her chin. As he/she swallows, the speech therapist pushes the patient's head forwards, inviting him/her to put up some resistance; at the same time, with the hand on the chin, he/she pushes downwards and backwards<sup>7 9-11</sup>.

## Eating stratagems

The first foods must be introduced in line with certain choices dictated by the different textures of the foods.

The first to be introduced are dense foods like puddings, mousses, mashed potatoes, soft cheese, cool yoghurt, to stimulate sensitivity (which is initially poor) and should respect the patient's favourite flavours to stimulate motivation. A whole, creamy meal is then introduced, of which at least 70% must be eaten before it can be replaced with a normal solid meal.

## References

- <sup>1</sup> Arnoux-Sindt B. *Readaptation fonctionnelle après chirurgie reconstructive laryngée* Cah ORL 1991;9:26-35.
- <sup>2</sup> Bergamini G, Luppi MP, Anceschi T, et al. *La riabilitazione precoce nelle laringectomie funzionali orizzontali*. Acta Phon Latina 1992;14:3-12.

It is best to avoid pasta in broth, short pasta shapes, spaghetti and rice, raw vegetables with filaments, pulses, acidic and spicy foods, all foods with both solid and liquid components, juicy fruit and that with seeds (strawberries, kiwi fruit, orange, watermelon, melon, etc.).

Liquids are introduced last of all, starting with milk and fruit juices which are more flavoursome and denser than water. Fizzy drinks and alcoholic beverages should be avoided.

Whilst eating, it is important that the patient is in a peaceful environment, has time as long as necessary and is not surrounded by distracting factors (television, visitors)<sup>4 8 9</sup>.

## Voice recovery

Once the patient has been discharged, rehabilitation training continues on an outpatient basis for setting the neovoice. Patients who have undergone supraglottic laryngectomy do not usually require voice therapy.

The first step is to teach the patient how to perform correct costo-diaphragmatic breathing<sup>3 5</sup>.

In the case of GHL, training will follow the schedule indicated previously for false cord voice compensation following cordectomy<sup>3</sup>.

In other types of horizontal functional laryngectomy (CHEP, CHP, THEP, THP), the arytenoid neovoice is obtained by making a rasp that is articulated in the form of short, energetic vowels: /a/ /o/ /e/ /i/ /u/, using chest, arm and head pushing.

This is followed by nasal /m/, in syllables: MA, MO, ME, MI, MU, prolonging the final vowel with strong intensity each time; with the rapid and energetic production of the sonant and surd velar occlusive + uvular vibration + vowel: GRA, GRO, GRE, GRI, GRU, KRA, KRO, KRE, KRI, KRU; with the production of the syllables with single and double surd and sonant occlusives (KA, KO, KE, KI, KU; KAKA, KOKO, KEKE, KIKI, KUKU) and with various vowel combinations (KIKIKE, GHIGHIGA, GOGOGHE, GHIEGHIE).

The number of syllables repeated depends on the patient's phonatory duration.

Treatment will continue with the reading of the first words with a sonant and surd occlusive phonemic component, followed by a mixed component, then by reading nursery rhymes, sentences and, finally stories<sup>1 4 7 9 12</sup>.

<sup>3</sup> Bonnet P, Arnoux-Sindt B, Guerrier B, et al. *La chirurgie reconstructive du larynx. A propos de la readaptation fonctionnelle des malades opérés de C.H.E.P. et C.H.P.* Cah ORL 1988;2:465-79.

<sup>4</sup> Danoy MC, Heuillet G, Inedjian JM, et al. *Laryngectomies reconstructives: que faire en rééducation et pourquoi?* Rev Laryngol Otol Rhinol (Bord) 1988;109:379-82.

- <sup>5</sup> Demard D, Demard F. *Reéducation vocale après laryngectomie partielles?* Rev Laryngol Otol Rhinol (Bord) 1984;105:415-7.
- <sup>6</sup> Le Huche F, Allali A. *La Voce*. Vol. 3. Milano: Masson Italia; 1996, p. 55-7.
- <sup>7</sup> Luna-Ortiz K, Nunez-Vlencia ER, Tamez-Velarde M, et al. *Quality of life and functional evaluation after supracricoid partial laryngectomy with cricothyroidopiglottopexy in Mexican patients*. J Laryngol Otol 2004;118:284-8.
- <sup>8</sup> Makeieff M, Barbotte E, Giovanni A, et al. *Acoustic and aerodynamic measurements of speech production after supracricoid partial laryngectomy*. Laryngoscope 2005;115:546-51.
- <sup>9</sup> Romani U, Bergamini G, Ghidini A, et al. *Le laringectomie sub-totali ricostruttive nel trattamento del cancro della laringe*. Acta Otorhinolaryngol Ital 1996;16:526-31.
- <sup>10</sup> Karasalioglu AR, Yagiz R, Tas A, et al. *Supracricoid partial laryngectomy with cricothyroidopexy and cricothyroidopiglottopexy: functional and oncological results*. J Laryngol Otol 2004;118:671-5.
- <sup>11</sup> Segre R. *La comunicazione orale normale e patologica*. Torino: C.G. Edizioni Medico-Scientifiche; 1976, p. 390-4.
- <sup>12</sup> Sparano Ruiz AC, Weinstein GS. *Voice rehabilitation after external partial laryngeal surgery*. Otolaryngol Clin North Am 2004;37:637-53.

# Surgical rehabilitation

## *Riabilitazione chirurgica*

G. BERGAMINI, L. PRESUTTI, M. ALICANDRI CIUFELLI, F. MASONI  
ENT Department, University Hospital of Modena, Italy

For many years, the alternative to functional procedures in which the glottic or supraglottic level are preserved (cordectomy of varying extents, supraglottic horizontal laryngectomy) was total laryngectomy, as replacement sphincteric function was not believed to be possible.

The merit goes to Serafini<sup>1</sup>, despite the initial failures of tracheohyoidoepiglottopexy, for having stimulated the research into techniques to replace total laryngectomy<sup>2-4</sup> making it possible to reconstruct the aerodigestive crossroads, whilst maintaining the three functions of the larynx, despite the absence of the “conventional” structures (epiglottis, false cords, vocal cords) assigned to sphincteric function.

All this was facilitated by the simultaneous development of speech therapy strategies, thanks primarily to the French schools, aimed at readapting swallowing first and subsequently speech to the neoglottis characterised by a dynamic opposition between the anterior structures (epiglottis or base of the tongue) and one or two arytenoids to the rear, which must maintain good movement for arytenoid health.

In the absence of the bases for adequate functional recovery (correct surgical technique with preservation of the function of the laryngeal nerves, correctly performed reconstruction, immediate post-operative rehabilitation) or in the presence of various types of complication that cause non-optimal anatomic and functional sequelae, recovery of the swallowing function can be problematic especially in patients whose neurological situation does not require efficacious neuronal plasticity.

In some cases, due to the persistence of swallowing difficulties, with progressive weight loss and the occurrence of repeated episodes of aspiration with bronchopneumonic complications, use of PEG can constitute a provisional measure for allowing an extension of the rehabilitation programme. If the functional situation does not improve to allow adequate, risk-free eating, patients are often offered total laryngectomy.

In order to avoid this kind of conclusion to the treatment programme, which undoubtedly represents a failure for functional surgery and is deeply frustrating for a patient who has gone through a difficult and exasperating postoperative phase in the hope of avoiding permanent tracheostomy, since the late 1980s, some Authors<sup>5-7</sup> have suggested surgical methods that aim to improve neoglottic competence and

consequently, the functions (swallowing and voice) related to the sphincteric ability of the larynx. This functional rehabilitational surgery is gradually being adopted, after the early experiences based exclusively on injective laryngoplasty techniques in the light of more detailed evaluations of the various causes of deglutition failure.

Moreover, only with injective methods is it possible to find solutions to minimal pre- and post-deglutition disorders that, due to the presence of an efficacious expulsive cough, do not constitute a risk for the lower airways, rather a cause of inconvenience for the patient in social situations, which thus compromises quality of life.

In parallel with the attempts to solve the problems of neoglottic insufficiency, a voice surgery technique has been developed with the aim of improving glottic competence following cordectomy to improve voice quality and eliminate the phonoasthenia that often represents the greatest handicap for these patients<sup>8-11</sup>.

## **Corpectomy**

In cordectomies, the functional sequelae are exclusively voice-related. Difficulties swallowing liquids for the few days immediately after the procedure are temporary and resolve spontaneously in a few days. Dysphonia can be the direct consequence of glottic insufficiency, the effect of an anterior adherence (often inevitable when resection also affects the anterior commissure) or caused by supraglottic compensations (from false cords or arytenoepiglottic) favoured by certain situations, such as: oedematous arytenoids, pre-existent hypertrophy of the false cords, extensive glottic resections, retroverted epiglottis, spontaneous, unfavourable compensation due to the absence of postoperative speech therapy.

Speech therapy can resolve speech problems after limited resection (type I and II cordectomies) or after type III cordectomies with the formation of significant neocord scarring. It is also the first line of treatment since any late voice surgery, indicated in the event of unsatisfactory results after rehabilitation, is not recommended for at least 6 months.

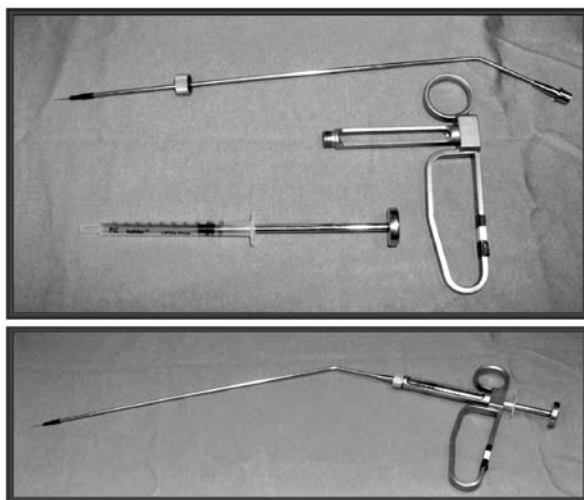
Some Authors have suggested immediate surgical rehabilitation, during the same surgical session as the cordectomy, using autologous fat<sup>12</sup>. On the basis of these experiences, we introduced into our clinical practice primary

surgical rehabilitation using hyaluronic acid<sup>13</sup> with both augmentation aims and in order to improve the scarring processes with a stiffer neocord and that therefore can be applicable also to mucosectomy (type I cordectomy). This makes it possible to obtain a volume increase without additional morbidity around the harvesting site as occurs for fat and with a consequent reduction in the time needed to perform the procedure. We use a Medtronic Xomed Laryngeal Injector with a 27-gauge needle (Orotracheal injection set). Since hyaluronic acid is usually highly viscous and consequently offers a certain resistance when injected using a small gauge needle, we developed a metal plunger that makes it possible to exert adequate pressure that can be varied during the injection (Fig. 1).

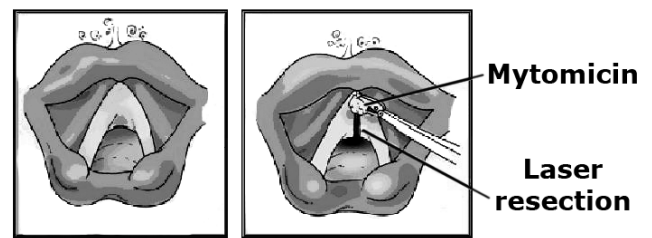
Deferred rehabilitation surgical procedures secondary to cordectomy can be performed using injective laryngoplasty, using biological materials (autologous fat, bovine collagen, homologous collagen, hyaluronic acid) or synthetic materials (polydimethylsiloxane – PDMS) and with structural surgery<sup>14-18</sup>. Whereas fat, collagen and hyaluronic acid can change in volume over time, due to partial reabsorption, PDMS is stable and non-reabsorbable. The main problem related to injective laryngoplasty is the unpredictability of the size of volume increase in the neocord and the homogeneity of the distribution of the material, as these two factors depend on the distensibility of the scar tissue.

In the case of a neocord that is small and/or very close to the thyroid cartilage, and that cannot therefore be enlarged by injection, type I thyroplasty must be performed, using the Goretex technique that allows a gradual detachment of the perichondrium and simultaneous medialisation of the neocord. Goretex thyroplasty is preferable to

### Hyaluronic acid: Syringe for injection



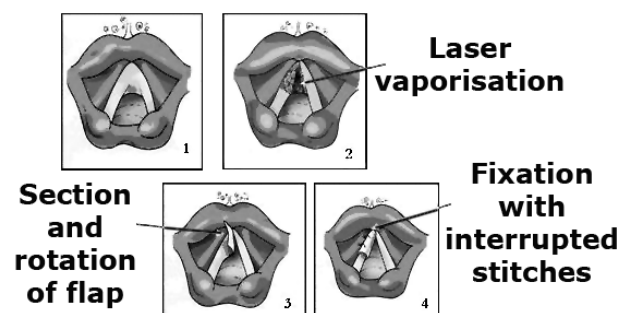
**Fig. 1.** Syringe with a particular metal plunger that makes it possible to exert adequate pressure that can be varied during the injection.



**Fig. 2.** Resection of the anterior scarring with application of mitomycin.

techniques using implants because it is modifiable and presents less risk of extrusion. In the case of procedures involving the commissural region or the juxta commissural one, the neocord can be inexistent with the newly formed perichondrium particularly close to the cartilage. This results in marked anterior glottic insufficiency that cannot be solved either with endoscopic enlargement or by external medialisation. In such situations, Zeitels et al. suggested a laryngoplasty of the anterior commissure that can be integrated with an injective method on the rear two-thirds of the neocord<sup>14 16</sup>.

In the event of supraglottic false cord compensation, if this is adequate and the voice intense enough, particularly in male patients, voice surgery could take the form of helping the ventricular bands to meet (injective laryngoplasty). If glottic compensation is believed to be more favourable and feasible, it is achieved by laser resection of the false cords and surgical rehabilitation of the glottic level. When arytenoepiglottic compensation occurs, replacement, if deemed to be advantageous, will involve partial laser resection of the arytenoid hood or of the aryepiglottic fold and voice surgery treatment of the glottic level. In some cases, dysphonia occurs secondary to the formation of scar tissue in the anterior commissure. The surgical solution can either be a resection of the anterior scarring with application of mitomycin



**Fig. 3.** Reconstruction of the commissure using a flap of adequately de-epithelised scar tissue and thinned and fixed with interrupted stitches on to the upper face of one of the two vocal cords, following removal by laser vaporisation of the mucosal coating.

(Fig. 2) in an attempt to avoid relapses or reconstruction of the commissure using a flap of adequately de-epithelised scar tissue and thinned and fixed with interrupted stitches on to the upper face of one of the two vocal cords, following removal by laser vaporisation of the mucosal coating (Fig. 3).

### Supraglottic laryngectomies

Functional problems are almost exclusively related to cases of supraglottic laryngectomy extended to the arytenoid and the vocal cords, however “classic” procedures can present sequelae if the motility of one or both arytenoids is compromised, if mucosal flaps compromise respiratory tract patency, due to a reduced sensitivity that does not allow an efficacious adductory reflex of the vocal cords. The coexistence of these factors will worsen the dysphagia. In the case of breathing difficulties, the microlaryngoscopic approach using a laser technique will make it possible, either through the resection of the mucosal flap or performance of a rear cordotomy to restore respiratory tract patency and to remove of the tracheostomy tube. If one side of the larynx is immobile or one vocal cord absent, glottic insufficiency will be corrected by injective laryngoplasty using the same technique as for laryngeal monoplegia<sup>19</sup>. Botulinum A toxin or cricopharyngeal myotomy may be considered in cases of sensitivity deficits and/or abnormal cricopharyngeal tone.

### Subtotal laryngectomies

In the case of subtotal laryngectomies, the most frequent complication from a functional point of view is the persistence of swallowing problems of varying importance, characterised by a risk of bronchopulmonary infection or cause discomfort while eating (need for accentuated facilitating postures during swallowing, sudden coughing, stagnation of foods causing numerous rasps or need to perform liberating manoeuvres of various types) with consequent difficulties eating certain foods and a tendency to avoid social events<sup>20</sup>. Dysphagia is often directly related to poor compensation voice sonority, as both swallowing and voice are conditioned by the sphincteric capacity of the cricoarytenoid unit. However, functional failure is sometimes of the respiratory type, making it impossible to decannulise patients.

The main causes of neoglottic insufficiency are: ankylosis or arytenoid paralysis, backward displacement of the cricoid in relation to the hyoid bone, morpho-functional deficiency of the base of the tongue, however deglutition can also be compromised by other situations, such as: sensitivity deficit of the pharyngeal mucosa and/or neoglottis, preventing the triggering of the pharyngeal phase and the adductory laryngeal reflex; increase in crico-pharyngeal tone or narrowing due to scarring of

the mouth of the oesophagus, which by slowing down the pharyngeal phase of swallowing prolong contact between the bolus and the neoglottic aditus, thus increasing the risk of post-deglutition aspiration; presence of atonic piriform fossae or scarring roughness that cause bolus stagnation, leading to a prolonged feeling of presence of a foreign body and constituting a cause of post-deglutition aspiration; separation of the reconstruction, a factor that is particularly important in the absence of the epiglottis since moving the neoglottis away from the hyoid bone vanquishes the protective mechanism of the base of the tongue and compromises the efficiency of arytenolingual compensation, due to the formation of a recess between the hyoid bone and cricoid cartilage at the point in which the arytenoid usually comes into contact with the base of the tongue. It must not be forgotten that, particularly in elderly patients, it is possible that a bone spur (DISH syndrome), may compress the oesophagus, constituting an obstacle to the progression of the bolus, which thus becomes an important concomitant cause of postoperative dysphagia, an eventuality that should be explored with a preoperative l-l projection x-ray of the cervical spine.

The main causes of respiratory impairment are: persistence of oedema or arytenoid mucosal flap, stenosis of the neoglottis due to membranous or structural causes due to the collapse of the cricoid cartilage (fracture caused by reconstruction traction or chondritis sequelae), forward displacement of the cricoid due to incorrect reconstruction alignment.

Video fibroendoscopy is the fundamental technique for the diagnostic approach to these problems, as it is able to document the anatomic and functional situation, in addition to a sensitivity test and, using boli of varying textures, provides an assessment of deglutition (FEES) that, in the presence of a tracheotomy can also be completed with a hypoglottoscopic examination<sup>21</sup>.

The fibroendoscopic examination of swallowing is irreplaceable also for preoperative planning of a surgical correction by injective laryngoplasty in direct microlaryngoscopy, as during the procedure it is not possible to predict the injection points that will make it possible to correct the disorder. During fibroscopy, an expert eye is able to guess the presence of a reconstruction separation (Fig. 4) requiring confirmation using a X-ray study: a laterolateral projection X-ray of the cervical spine (Fig. 5) and CT of the larynx with 3D reconstructions (Fig. 6), which is also useful for identifying any cervical bone spurs.

Video fluoroscopy can be used as a complement to FEES to document the extent of inhalation with the various barium textures, to identify crico-pharyngeal hypertone or scarring stenosis.

Rehabilitation surgery is performed via the cervicotomy route (reconstruction review and cervical spinal surgery for Forestier’s syndrome), direct suspended microlarynx



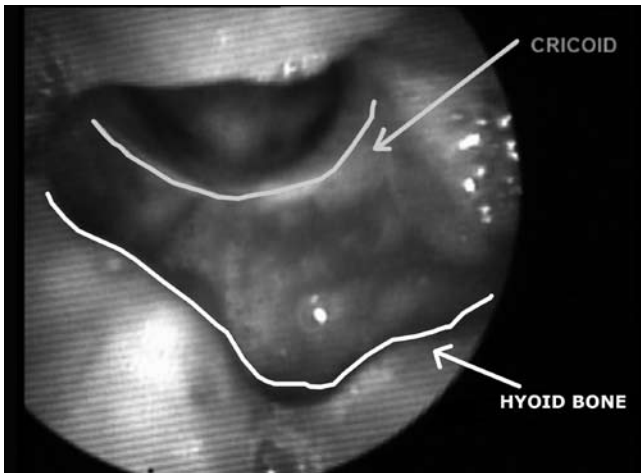


Fig. 4. Fibroendoscopy showing a reconstruction separation.

goscopic procedures (laser resection of the arytenoid mucosal flap or membranous stenosis, laser myotomy of the crico-pharyngeal muscle and injective laryngoplasty), fibroendoscopic arytenoid augmentation.

Reconstruction review can correct situations of separation and anterior or posterior cricothyroid misalignment and membranous and cartilaginous stenosis, cervical spine surgery with prevascular access makes it possible to eliminate compression on the oesophagus by filing the bone spurs. In direct microlaryngoscopy, as well as recanalisation of the respiratory tract, augmentation techniques can be used to reduce or eliminate neoglottic insufficiency and to exclude or minimise any scarring furrows responsible for food stagnation.

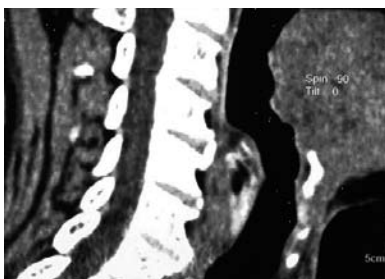


Fig. 5. Laterolateral projection X-ray of the cervical spine.

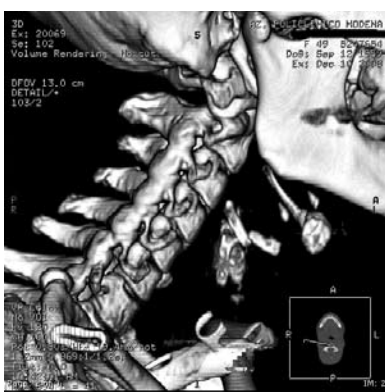

Fig. 6. CT of the larynx with 3D reconstructions.

Materials used depending on the infiltration site

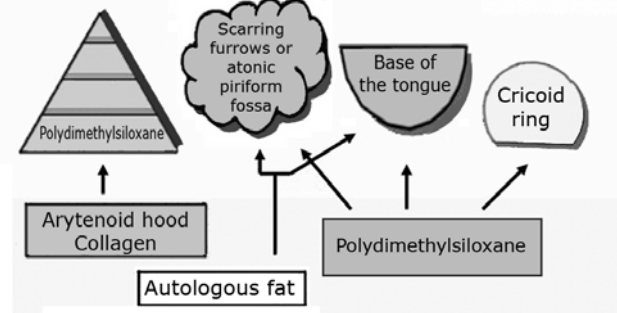


Fig. 7. Materials that can be used depending on the infiltration site.

The materials that can be used, depending on the infiltration site, are shown in Figure 7. Our experience is based on the use of Vox-Implants (Uroplasty, Inc.), whose injection site stability and absence of reabsorption allow a stable result. This product is constituted by a suspension of PDMS grains with a diameter of between 100 and 200 µm in a polyvinylpyrrolidone (PVP) that acts as a thinner and carrier. The PVP is subsequently reabsorbed by the lymphoreticular system, whilst the particle of PDMS, thanks to their size and superficial texture, which leads to the formation of a connective lattice, do not migrate. The injection system is constituted by a gun whose plunger progresses in steps, each time the lever is pressed. It adapts perfectly to the syringe containing the material and the Luer Lock type connection constitutes a solid graft with the needle in the pack. It is malleable enough to be shaped so as to allow the surgeon optimum surgical field visibility and correct needle tip direction, which is essential for positioning the implant correctly.

The injection sites are indicated in Figure 8. In general, 2 or 3 cc of PDMS only are used.

Subtotal laryngectomies  
Injective laryngoplasties: site of injection

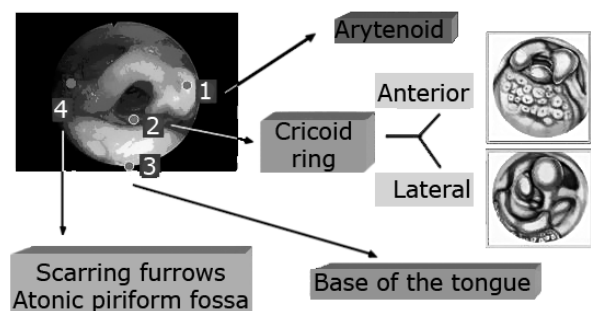


Fig. 8. Injection sites.

One of the sites that most often requires intervention is the front part of the neoglottis in correspondence to the cricoid ring and/or adjacent base of the tongue. Also in the case of a cricohyoidoepiglottopexy, an injection at the base of the tongue can be useful for positioning the suprahyoid epiglottis further back. The aim of the injection here is to reduce the anteroposterior gap caused by incomplete contact between the arytenoid(s) and the base of the tongue or the laryngeal face of the epiglottis. Another important injection site is the lateral side of the neoglottis to overcome the lateral gap that is sometimes present either on the side of the removed arytenoid or because the preserved arytenoid tilts without performing any forward sliding movement. The lateral part of the neoglottis can constitute an inhalation site when the piriform fossa is absent, atonic or scarred. This situation, and even scarring furrows that may form in other sites adjacent to the neoglottic aditus constitute the ideal condition for post-deglutition inhalations.

It is important not to overcorrect as the material cannot be reabsorbed and the increase in volume obtained is stable. The quantity to be injected must be carefully evaluated to avoid an excessive reduction in lumen taking into consideration also a possible mild post-operative oedema that can be avoided by administering cortisone therapy on the day of the procedure. The presence of the anaesthetic tube preserves the calibre, which avoids the risk of an exces-

sive reduction in respiratory tract patency. During infiltration, it is appropriate to make sure that adequate filling occurs. An absence of filling suggests that the material has been introduced too deep or that the material is sliding towards sites of lesser tissue resistance with a consequent inefficacy of the procedure. Lastly, it should be remembered that excessively superficial infiltration, particularly under pressure, can cause later extrusion, thus vanquishing the results obtained. It can be necessary to intervene in steps, particularly when scar tissues do not allow the first injection to infiltrate an adequate quantity of material and obtain the volume increase needed to correct the functional disorder. Some Authors<sup>22</sup> use the fibroendoscopic approach using instruments that bend with the operational channel, allowing the introduction of a 25-gauge needle. This technique makes it possible to intervene almost exclusively on the arytenoid hood and the material currently used is collagen, which requires a thin needle for injection. Although as a material, fat is suitable for this area, it requires a larger infiltration needle, to dispense the pressurised substance easily.

In patients with hypertonic oesophageal mouths or with a pharyngeal phase slowdown, botulinic toxin can be injected into the cricopharyngeal muscle or a myotomy performed. Both procedures can be performed either endoscopically or via the external route<sup>23-26</sup>.

## References

- Serafini I. *Laryngectomy totale con mantenimento della respirazione per vie naturali*. Minerva O.R.L. 1970;20:73-84.
- Mayer EH, Reider W. *Technique de laryngectomie permettant de conserver la perméabilité respiratoire (la crico-hyoido-pexie)*. Ann Otolaryngol 1959;76:677-81.
- Piquet JJ, Desaulty A, Delacroix G. *La crico-hyoido-pexie. Technique opératoire et résultat fonctionnels*. Ann Otolaryngol Chir Cervicofac 1974;91:681-6.
- Labayle J, Bismuth R. *La laryngectomie totale avec reconstruction*. Ann Otolaryngol Chir Cervicofac 1971;88:219-28.
- Bessede SP, Sauvage JP, Morin R, et al. *Correction des troubles de déglutition après chirurgie partielle du pharyngolarynx par injection de collagène. Etude de 9 cas*. Ann Otolaryngol 1988;105:343-8.
- Remacle M, Hamoir M, Marbaix E. *Gax-collagen injection to correct aspiration. Problems after subtotal laryngectomy*. Laryngoscope 1990;100:663-9.
- Galetti G, Botti M, Croatto L, et al. *La riabilitazione delle insufficienze glottiche e neoglottiche*. Acta Otorhinol 1990;10:217-61.
- Galetti G, Bergamini G, Ghidini A, et al. *Surgical rehabilitation of glottal insufficiency after a cordectomy*. Medicine Biologic Environnement 1990;18:489-96.
- Galetti G, Bergamini G, Ghidini A, et al. *Insufficienza glottica e neoglottica: inquadramento clinico, diagnosi e terapia chirurgica con gax collagene*. In: De Vincentiis M, editor. *Chirurgia funzionale della laringe: stato attuale dell'arte*. Rel. Uff. LXXX Cong. Naz. S.I.O. e Ch. C.-F. Pisa: Pacini Editore; 1993, p. 123-42.
- Rotemberg M. *L'utilisation du collagène en réhabilitation glottique et vocale*. Cah ORL 1990;26:46-7.
- Remacle M, Marbaix E, Hamoir M, et al. *Correction of glottic insufficiency by collagen injection*. Ann. Otol Rhinol Laryngol 1990;99:438-44.
- Bolzoni Villaret A, Piazza C, Radaelli De Zinis LO, et al. *Phonosurgery after endoscopic cordectomies. I. Primary intracordal autologous fat injection after transmuscular resection: preliminary results*. Eur Arch Otorhinolaryngol 2007;264:1179-84.
- Molteni G, Bergamini G, Ricci Maccarini A, et al. *Autocrosslinked hyaluronan gel injections in Phonosurgery*. Otolaryngol Head Neck Surg 2010;142:547-53.
- Zeitels MS, Jarboe J, Franco RA. *Phonosurgical reconstruction of early glottic cancer*. Laryngoscope 2001;11:1862-85.
- Sittel C, Friedrich G, Zorowka P, et al. *Surgical voice rehabilitation after laser surgery for glottic carcinoma*. Ann Otol Rhinol Laryngol 2002;111:433-9.
- Zeitels MS. *Optimizing voice after endoscopic partial laryngectomy*. Otolaryngol Clin North Am 2004;37:627-36.
- Remacle M, Lawson G, Morsomme D, et al. *Reconstruction of glottic defects after endoscopic cordectomy. Voice outcome*. Otolaryngol Clin North Am 2006;39:191-204.
- Piazza C, Villaret AB, Radaelli De Zinis LO, et al. *Phonosurgery after endoscopic cordectomies. II. Delayed medi-*

- alization techniques for major glottic incompetence after total and extended resections. *Eur Arch Otorhinolaryngol* 2007;264:1185-90.
- <sup>19</sup> Bergamini G, Alicandri-Ciuffelli M, Molteni G, et al. *Therapy of unilateral vocal fold paralysis with polydimethylsiloxane injection laryngoplasty: our experience*. *J Voice* 2010;24:119-2.
- <sup>20</sup> Bergamini G, Alicandri-Ciuffelli M, Molteni G, et al. *Rehabilitation of swallowing with polydimethylsiloxane injections in patients who underwent partial laryngectomy*. *Head Neck* 2009;31:1022-30.
- <sup>21</sup> Ricci Maccarini A, Stacchini M, Salsi D, et al. *Trans-tracheostomic endoscopy of the larynx in the evaluation of dysphagi*. *Acta Otorhinolaryngol Ital* 2007;27:290-3.
- <sup>22</sup> Ricci Maccarini. A, Stacchini M, Salsi D, et al. *Surgical rehabilitation of dysphagia after partial laryngectomy*. *Acta Otorhinolaryngol Ital* 2007;27:294-8.
- <sup>23</sup> Schneider I, Thumfart WF, Pototschnig C, et al. *Treatment of dysfunction of the cricopharyngeal muscle with botulinum A toxin: introduction of a new, non-invasive method*. *Ann Otol Rhinol Laryngol* 1994;103:31-5.
- <sup>24</sup> Moerman MBJ. *Cricopharyngeal Botox injection: indications and techniques*. *Curr Opin Otolaryngol Head Neck* 2006;14:431-6.
- <sup>25</sup> Kaplan S. *Paralysis of deglutition, a post-poliomyelitis complication treated by section of the cricopharyngeus muscle*. *Ann Surg* 1951;133:572-3.
- <sup>26</sup> Lawson G, Remacle M. *Endoscopic cricopharyngeal myotomy: indications and technique*. *Curr Op Otolaryngol Head Neck Surg* 2006;14:437-41.

# Functional evaluation protocol

## *Protocollo di valutazione funzionale*

A. GHIDINI, M. TREBBI, A. PICCININI, L. PRESUTTI  
ENT Department, University Hospital of Modena, Italy

Correct deglutition is the result of a precise coordination of the many structures present in the head and neck, indeed, although the deglutition sequence can be influenced and controlled by inputs from the cortical centres, it is, first and foremost, a semiautomatic mechanism<sup>1</sup>.

These mechanisms need correct sensory information from the muscles and mucosae of the areas involved, to generate a coordinated sequence of muscle contractions that generate the act of deglutition.

Consequently, any involvement of the sensory or motor integrity of the oral cavity, pharynx or larynx can cause dysphagia.

Therefore, surgery on the above areas can potentially cause dysphagia of varying severity.

This calls for the need to evaluate the impact that surgery can have in terms of dysphagia and, when possible, the need to quantify it, in relation also to the patient's quality of life. Despite the increasing application of the "organ saving" concept, surgical treatment, often followed by radiotherapy, remains the treatment of choice for most cancer sites in the head and neck.

Radiotherapy too can cause worsening, with the appearance or exacerbation of dysphagia secondary to xerostomy or radio-treated soft tissue fibrosis.

Given the current increasingly careful attention of surgeons to functional aspects, surgery must always take into account the need for surgical radicality, the strategy for optimally preserving swallowing, speech and respiratory function, to optimise the patient's quality of life.

Since all patients having pharyngeal-laryngeal cancer surgery are at risk of dysphagia, it is fundamental to perform an evaluation before restoring oral feeding, also considering that according to recent studies, patients with dysphagia always tend to underestimate their condition.

For this reason, the patient should undergo an initial "bed-side" assessment, followed by a more detailed and thorough study able to identify any episodes of silent aspiration.

This evaluation must be scheduled according to the type of procedure, local oedema, the presence of postoperative complications (such as pharyngocutaneous fistula) and the patient's psychological conditions.

The functional protocol can be broken down into the analysis of the fundamental functions of the pharyngolaryngeal organ, i.e., an evaluation of swallowing, speech and

respiratory functions, which together contribute to influencing the patient's quality of life.

## **Assessment of swallowing**

FEES (Flexible endoscopic evaluation of swallowing) was described for the first time by Langmore, Schatz and Olsen, in 1988<sup>2,3</sup>, and allows evaluation using a flexible rhinofibrolaryngoscope via the transnasal route (optionally combined with a stroboscopic light source and, by digital video camera, to a video recorder) and, therefore, can only be conducted by a team of phoniatrists-speech therapists working in a fully-equipped clinic.

The tip of the fibroscope is introduced as far as the oropharynx, from which point the attitude of the structures that control swallowing are studied. Coloured jelled water can also be used.

The potential interference of local anaesthetic on this functional evaluation is controversial.

This technique allows a careful evaluation of:

- the anatomical integrity of the nasopharyngo-laryngo-hypopharyngeal area;
- the sensitive integrity of the pharyngolaryngeal structures;
- the patient's ability to protect his/her respiratory tract;
- the symmetry of pharyngeal constrictive ability and the simultaneous contribution of the lingual phase;
- programming of an injective functional therapy;
- the possibility to evaluate food residues in the pharynx, aspiration and incorrect ingestion.

In the evaluation of deglutition, in addition to FEES, *videofluoroscopy*<sup>4,5</sup> is a fundamental method as the analysis of the deglutition dynamic makes it possible to identify organic and functional abnormalities, thus allowing important therapeutic reflexes and giving the therapist suggestions concerning the compensation mechanisms that facilitate the act of deglutition, in an attempt to improve patients' quality of life.

Various types of contrast agent (small boli of fluid barium, small boli of high density barium, barium paste, solid meal) can be used for videofluoroscopy, thus allowing a detailed study of the various phases of deglutition (oral, pharyngeal, laryngeal and hypopharyngo-oesophageal). This allows us to identify various types of aspiration:

- predeglutition (before deglutition);

- intradeglutition (during deglutition);
- postdeglutition (after deglutition).

This technique also makes it possible to assess the morphology of the spine (marked kyphosis or DISH syndrome, for example, can favour episodes of aspiration) and obtain important information (in terms of bolus volume and viscosity, head position alterations) for rehabilitation strategy purposes.

Compared to videofluoroscopy, FEES has the following: *Advantages:*

- It is a safer method when there is a high risk of inhalation;
- It guarantees visual feedback for the patient;
- It can be performed on an outpatient basis even in subjects who cannot be transferred to a radiology centre;
- Absence of repeated exposure to radiations.

*Disadvantages:*

- It is difficult to evaluate bolus management in the oral cavity;
- Visualisation is difficult during the act of deglutition, close to the base of the tongue and on the rear wall of the pharynx;
- It is more difficult to evaluate microaspiration or bolus penetration very close to the act of deglutition.

The patients we analysed underwent self-assessment of their dysphagia, in particular using the “MDADI”.

### M.D. Anderson Dysphagia Inventory (MDADI) <sup>6</sup>

This test investigates the patient’s deglutition abilities, for which he/she is asked to choose the score that best describes their situation (from 1 to 5: strongly agree, agree, no opinion, disagree, strongly disagree).

- (1) My swallowing ability limits my day-to-day activities.
- (2) I am embarrassed by my eating habits.
- (3) People have difficulty cooking for me.
- (4) Swallowing is more difficult at the end of the day.
- (5) I do not feel self-conscious when I eat.
- (6) I am upset by my swallowing problem.
- (7) Swallowing takes great effort.
- (8) I do not go out because of my swallowing problem.
- (9) My swallowing difficulty has caused me to lose income.
- (10) It takes me longer to eat because of my swallowing problem.
- (11) People ask me, “Why can’t you eat that?”
- (12) Other people are irritated by my swallowing problem.
- (13) I cough when I try to drink liquids.
- (14) My swallowing problems limit my social and personal life.
- (15) I feel free to go out to eat with my friends, neighbours and relatives.
- (16) I limit my food intake because of my swallowing difficulty.

(17) I cannot maintain my weight because of my swallowing problem.

(18) I have low self-esteem because of my swallowing problem.

(19) I feel that I am swallowing a huge amount of food.

(20) I feel excluded because of my eating habits.

### Assessment of respiration

This allows us to assess the influence of the various types of partial resection of the laryngeal structures and identifies any influence of concomitant chronic bronchitis on the alteration of the flow-volume curve following partial laryngectomy surgery.

It is fundamentally based on *conventional spirometry* with the flow-volume curve represented according to the classification proposed by Miller and Hyatt (1973) <sup>7</sup> and Miller (1985) <sup>8</sup>.

It would thus be useful to standardise periodic spirometric evaluation in protocols that assess the various units after the stabilisation of the post-surgical functional situation.

### Assessment of speech

Perceptive assessment of dysphonia is performed using the *G.I.R.B.A.S. scale* <sup>9 10</sup>.

*Grade:* 1 mild, 2 moderate, 3 severe.

*Instability:* 1 mild, 2 moderate, 3 severe.

*Roughness:* 1 mild, 2 moderate, 3 severe (with diplophonia: d).

*Breathiness:* 1 mild, 2 moderate, 3 severe.

*Astenicity:* 1 mild, 2 moderate, 3 severe.

*Strain:* 1 mild, 2 moderate, 3 severe (with tremor: t).

We perform the spectroacoustic voice examination using the “*SIFEL protocol*” <sup>11</sup>:

- Registration of a standard message containing: name and surname; the numbers 1 to 10; the five vowels /i/, /e/, /a/, /o/, /u/ held for 4 seconds; a short line from a song (“Frère Jacques”);
- Multiparametric analysis of the vowel /a/ using MDVP;
- Spectrogram of the same vowel /a/ analysed with MDVP, assessing the H/N Ratio, the noise components according to the spectrographic classification of dysphonia (modified Yanagihara’s classification), checking for the presence of diplophonia and/or tremors;
- Spectrogram of the word /aiuole/, evaluating the mean Fo and noise components according to the spectrographic evaluation of dysphonia;
- Automatic phonetogram with glissandos of the vowel /a/;
- Maximum phonatory time (normal value > 10 sec.).

All patients are then asked to do self-assessment tests for their dysphonia, in particular we use:

### Voice Handicap Index (VHI-10)<sup>12</sup>

*Instructions: indicate the answer you believe to be most truthful in your experience*

0 = never; 1 = almost never; 2 = sometimes; 3 = almost always; 4 = always

- F 1. My voice makes it difficult for people to hear me.  
0 1 2 3 4
- P 2. I run out of air when I talk.  
0 1 2 3 4
- F 3. People have difficulty understanding me in a noisy room.  
0 1 2 3 4
- P 4. The sound of my voice varies throughout the day.  
0 1 2 3 4
- F 5. My family has difficulty hearing me when I call them throughout the house.  
0 1 2 3 4

- F 6. I use the phone less often than I would like to.  
0 1 2 3 4
- E 7. I'm tense when talking to others because of my voice.  
0 1 2 3 4
- F 8. I tend to avoid groups of people because of my voice.  
0 1 2 3 4
- E 9. People seem irritated with my voice.  
0 1 2 3 4
- P 10. People ask: "What's wrong with your voice?"  
0 1 2 3 4

|          |   |   |             |             |            |
|----------|---|---|-------------|-------------|------------|
| VHI-10 = | — | 0 | 1 Slight    | 2 Moderate  | 3 Severe   |
|          |   |   | alteration: | alteration: | alteration |
|          |   | 0 | 1-13        | 14-27       | 28-40      |

### References

- 1 Leonard R, Kendall K. *Dysphagia Assessment and treatment planning: a team approach*. San Diego, CA: Singular Publishing Group; 2007, 2<sup>nd</sup> edn.
- 2 Langmore SE, Schatz K, Olsen N. *Fiberoptic endoscopic examination of swallowing safety: a new procedure*. *Dysphagia* 1988;2:216-9.
- 3 Langmore SE, Logemann JA. *After the clinical bedside swallowing examination, what's next?* *Am J Speech Lang Path* 1991;1:13-20.
- 4 Logemann JA. *Evaluation and treatment of swallowing disorders*. San Diego, CA: College Hill Press; 1983.
- 5 Rasley A, Logemann JA, Kahrilas PJ, et al. *Prevention of barium aspiration during videofluoroscopic swallowing studies: value of change in posture*. *Am J Roentgenol* 1993;160:1005-9.
- 6 Chen AY, Frankowski R, Bishop-Leone J, et al. *The development and validation of a dysphagia-specific quality-of-life questionnaire for patients with head and neck cancer: the M.D. Anderson dysphagia inventory*. *Arch Otolaryngol Head Neck Surg* 2001;127:870-6.
- 7 Miller RD, Hyatt RE. *Evaluation of obstructing lesions of the trachea and larynx by flow volume loops*. *Am Rev Respir Dis* 1973;108:475-81.
- 8 Miller A. *Pulmonary function tests in clinical and occupational lung disease*. New York/London/Toronto: Grune and Stratton Inc.; 1985
- 9 Hirano M. *Psycho-acoustic evaluation of voice*. In: Hirano M. *Clinical Examination of voice*. New York: Springer-Verlag; 1981.
- 10 Dejonckere P, Remacle M, Fresnel-Elbaz E, et al. *Reliability and clinical relevance of perceptual evaluation of pathological voices*. *Rev Laryngol Otol Rhinol (Bord)* 1998;119:247-8.
- 11 Ricci Maccarini A, Lucchini E. *La valutazione soggettiva ed oggettiva della disfonia. Il protocollo SIFEL*. In: *Relazione ufficiale al XXXVI Congresso Nazionale della Società Italiana di Foniatria e Logopedia*. *Acta Phon Latina* 2002;24:13.
- 12 Rosen, C, Lee, A, Osborne, J, et al. *Development and Validation of the Voice Handicap Index-10*. *Laryngoscope* 2004;114:1549-56.

Address for correspondence: Dr. A. Ghidini, U.O.C. Otorinolaringoiatria, Azienda Ospedaliero-Universitaria di Modena, via del Pozzo 71, 41100 Modena, Italy.

# Our case load

## *La nostra casistica*

A. PICCININI, M. TREBBI

ENT Department, University Hospital of Modena, Italy

Numerous surgical techniques can be used for conservative laryngeal cancer treatment. In all cases, the goal is to preserve laryngeal function as far as possible and, at the same time, to observe, as rigorously as possible the principles of oncological radicality.

Between 1<sup>st</sup> January, 2003 and 1<sup>st</sup> January, 2009, 122 functional reconstructive laryngectomies were performed at the ENT Clinic of Modena General Hospital.

The following types of procedure were performed:

- Cricohyoidoepiglottopexy (CHEP) or laryngectomy using the Mayer-Piquet technique: 56 patients had this type of surgery.
- Cricohyoidopexy (CHP) or laryngectomy using the La-bayle technique: 20 patients.
- Supraglottic horizontal laryngectomy (SHL) using Alonso's technique: 35 patients.
- Glottic horizontal laryngectomy using Calero-Teatini's technique: 4 patients.
- Supracricoid hemipharyngectomy: 2 patients.
- Tracheohyoidopexy (THP): 5 patients.

Patients had a mean age of 65 years (range 48 - 84 years).

The nasogastric tube removal date and discharge date were calculated for all patients. The data regarding decannulation was calculated in all patients except those who had to follow a subsequent cycle of radiotherapy to complete treatment, as these patients were discharged with the tracheotomy tube, as a precaution, in view of their subsequent radiotherapy.

In the light of these data, the nasogastric tube was removed, on average, on post-operative day 14 (range: 3-38 days), on average, patients were decannulated on day 23 (range: 12-88 days), discharge was, on average, on day 27 (range: 11-90 days).

Deglutition training ended at discharge. The deglutition data refers to all patients, who attended a 3-month follow-up visit.

Two deglutition assessment scales were used:

- "Dysphagia Score" (Table I) which provides a score on the basis of the patient's medical history.
- "Penetration-Aspiration scale" (modified version) (Table II) performed after a fibrolaryngoendoscopic evaluation of swallowing (FEES).

As speech rehabilitation takes place primarily after discharge, the findings concerning deglutition concern all pa-

**Table I.** Dysphagia Score.

| Score | Symptoms  |
|-------|---|
| 1     | Normal deglutition  |
| 2     | Rare coughing when swallowing saliva, not related to the introduction of food |
| 3     | Rare coughing when introducing food   |
| 4     | Frequent coughing when introducing food                                       |
| 5     | Frequent cough not related to the introduction of food                        |
| 6     | Pulmonary aspiration  |

**Table II.** Penetration-Aspiration scale modified.

| Score | Criteria  |
|-------|---|
| 1     | The material does not enter the respiratory tract   |
| 2     | The material enters the respiratory tract, comes into contact with the neoglottis, stimulates the cough reflex and is completely expelled     |
| 3     | The material enters the respiratory tract, comes into contact with the neoglottis, stimulates the cough reflex and is not completely expelled |
| 4     | The material enters the respiratory tract, passes the neoglottis, stimulates the cough reflex and is completely expelled                      |
| 5     | The material enters the respiratory tract, passes the neoglottis, stimulates the cough reflex and is not completely expelled                  |
| 6     | The material enters the respiratory tract, passes the neoglottis, but does not stimulate any reflex   |

tients, whereas the voice findings concern those patients able to attend speech therapy sessions at our service only. As far as the vocal results were concerned, we used Yanagihara's classification (modified by Ricci Maccarini and De Colle) for the vowel /a/, this classification involves three types of spectrogram.

As far as the aerodynamic indices were concerned, we took into account the maximum phonatory time on a sustained vowel /a/. We also took into account the patients' self-assessment, filling in the Voice Handicap Index (ten-item version): each question was given a score, these scores will be added together and the patient's perception of his/her voice and to what extent it is invalidating will be evaluated (0: voice normal; 1-13: slight alteration; 14-27: moderate alteration; 28-40: severe alteration).

Having analysed the post-operative complications, we observed that 16 patients had persistent respiratory problems: of these, 4 had a supraglottic laryngectomy, 1 had a cricothyroidopexy, 9 patients had a cricothyroidoepiglottopexy and 2 patients had a tracheo-tyroidopexy.

In 10 cases, it was necessary to perform a laser mucosal flap resection to remove the cause of respiratory problems. In the others, the problem resolved spontaneously or following cortisone therapy.

Dysphagia problems were encountered in 28 patients: of these, 12 had a supraglottic laryngectomy, 10 had a cricothyroidopexy, 5 patients had a cricothyroidoepiglottopexy and 1 patient had a supracricoid hemipharyngectomy.

In most patients (17 patients), the dysphagia problem was resolved following a prolonged cycle of deglutition therapy. In one patient, a percutaneous gastrostomy (PEG) had to be placed and was subsequently removed once a correct deglutition dynamic had been obtained after a cycle of therapy.

Another patient with irresolvable dysphagia problems underwent surgical totalisation. Surgical treatment with injective laryngoplasty to resolve dysphagia problems, was performed in 9 patients.

Considering the patients undergoing surgical rehabilitation only, and including also patients with dysphagia problems following a partial laryngectomy performed in another centre, the caseload was composed as follows:

- 4 patients, of whom 2 had a CHP, and 2 had CHEP in another centre, required reconstruction review surgery;
- 13 patients had an injective laryngoplasty with Vox Implants; of these, 6 underwent CHEP, 2 CHP, 4 SHL and 1 patient had supracricoid hemipharyngolaryngectomy (of these, 4 had surgery in another centre). Only one of these patients, in addition to an injective laryngoplasty, also had reconstruction review surgery combined with removal of cervical spinal bone spurs.

All patients submitted to injective laryngoplasty underwent pre- and post-operative dysphagia evaluation using the Dysphagia Score and a FEES, the results of which were subsequently quantified using the Modified Penetration-Aspiration Scale.

By comparing pre- and post-operative data, all patients

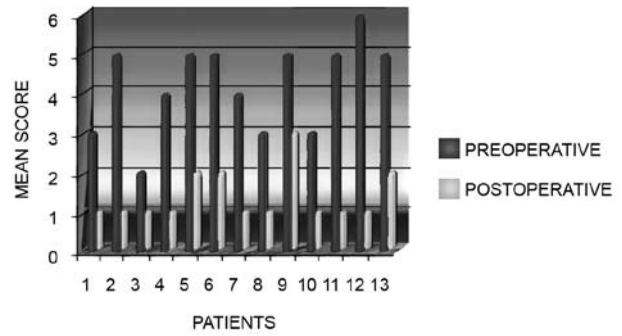


Fig. 1. Pre- and post-operative Dysphagia Score.

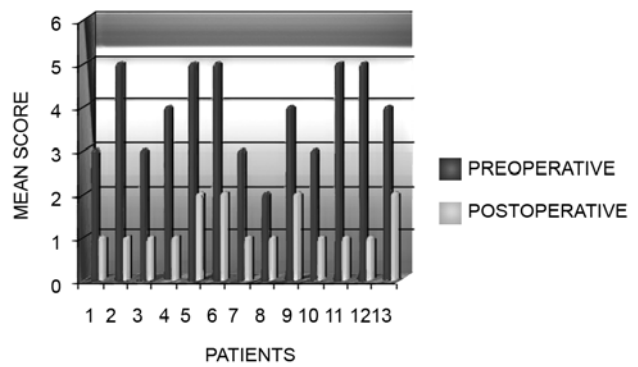


Fig. 2. Modified pre- and post-operative Penetration-Aspiration Scale.

showed a statistically significant improvement, with an average improvement of 2.6 for the Dysphagia Score (Fig. 1) and an average improvement of 2.1 on the Modified Penetration Aspiration Scale (Fig. 2).

Polydimethylsiloxane is well known in speech surgery for its safety and stability over time, as reported in many studies. Our results showed that injective laryngoplasty using this material can prove a valid option in deglutition rehabilitation surgery following subtotal laryngectomy. FEES also proved to be a valid examination for the identification of anatomical alterations that cause incorrect food bolus passage in the respiratory tract during deglutition, and is also able to provide important information on the correct sites for Vox Implant injection, which is indispensable for correct surgical planning.

Address for correspondence: Dr. A. Piccinini, U.O.C. Otorinolaringoiatria, Azienda Ospedaliero-Universitaria di Modena, via del Pozzo 71, 41100 Modena, Italy.